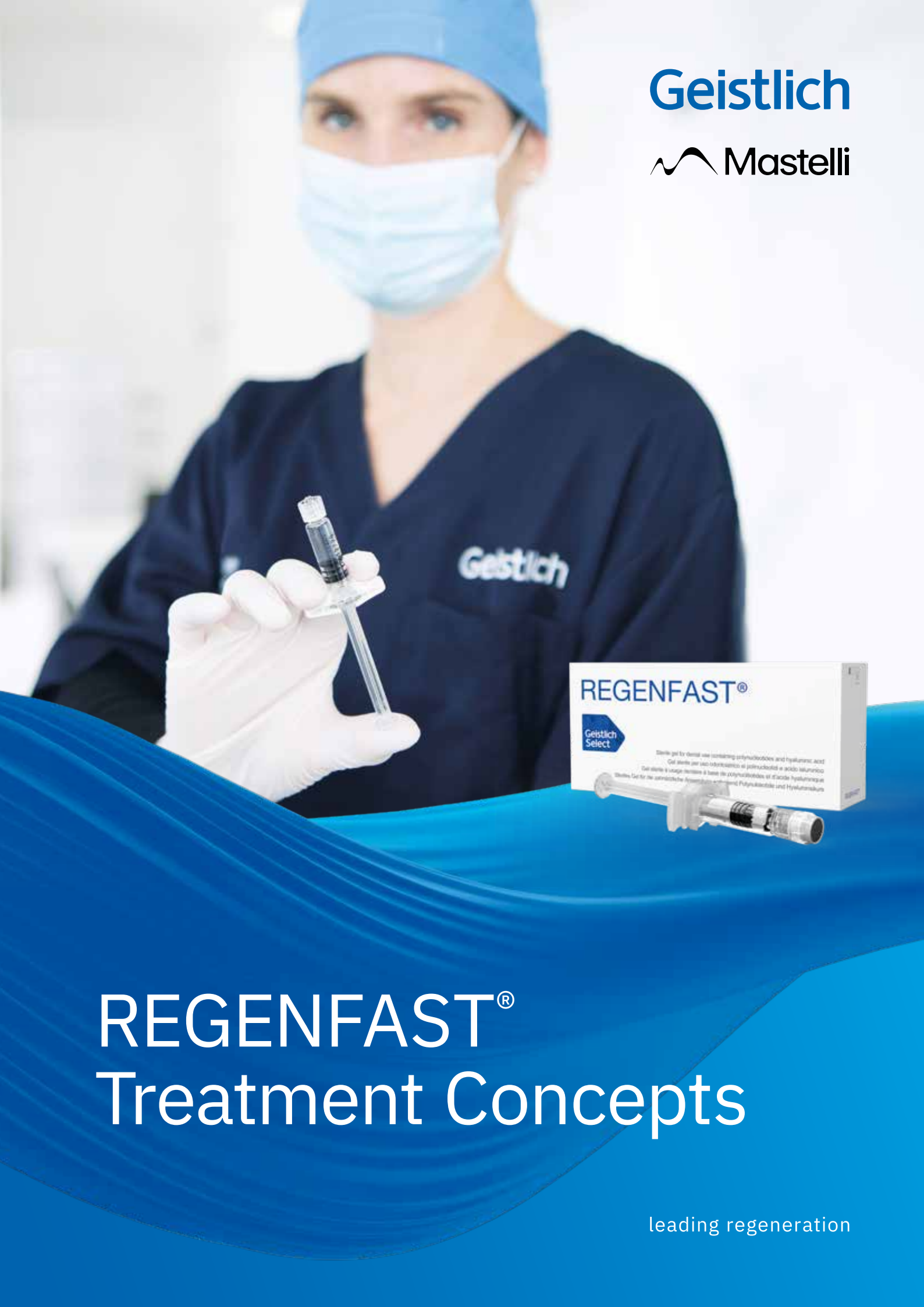

Geistlich

Mastelli



REGENFAST® Treatment Concepts

leading regeneration

Content

- 3** Protect tissues
Promote healing
- 4–5** Treatment options tailored to needs
Earn your patients' trust
- 6–7** Tips & tricks from leading experts based
on their experience with REGENFAST®
- 8–9** The science behind REGENFAST®
- 10** GBR with REGENFAST®:
Preliminary histological features
Prof. Claudia Dellavia
- 11–15** **Periodontal treatment**
Dr. Roberto Rotundo
Dr. Roberto Abundo
Prof. Francesco Cairo
Dr. Raffaele Cavalcanti
Dr. Philippe Doucet
- 16–20** **Soft tissue regeneration**
Prof. Daniele Cardaropoli
Dr. Federico Rivara
Dr. Jonathan Semtob
Dr. Marco Zeltner
Dr. Sébastien Monlezun
- 21–23** **Extraction socket management**
Dr. Federico Rivara
Prof. Leonardo Trombelli
Dr. Marco Zeltner
- 24–26** **Minor bone augmentation**
Dr. Elliott Ballantyne
Dr. Mario Beretta
Dr. Emmanuelle Ettetdgui
- 27–28** **Major bone augmentation**
Dr. Alfonso Rao
Dr. Jacques Hassid
- 29** **Peri-implantitis**
Dr. David Palombo
- 30** **Oral surgery**
Dr. Alberto Pispero
- 31** **Product range**

Protect tissues Promote healing

Whether periodontal, bone or soft-tissue regeneration, healing is one of the most crucial aspects in ensuring the success of regenerative treatments.

What's more, patients nowadays generally want an approach that will lead to rapid healing, a more physiological repair and their treatment ending sooner rather than later. Have you been looking for a product that you can integrate into your daily practice to cater to such patient needs?

Introducing REGENFAST®: a new product in regenerative dentistry that features a unique combination of polynucleotides and hyaluronic acid, designed to protect the tissues of the oral cavity and promote a more rapid and physiological repair and trophism.¹

This Treatment Concepts Brochure provides information on REGENFAST®, its use alone or in combination with Geistlich biomaterials, possible treatment areas, clinical cases and handling advice from leading dental clinicians who have already used REGENFAST® to treat more than 100 patients in five countries, with follow-up periods of up to 1.5 years.



Geistlich Bio-Oss® mixed with REGENFAST® in a 3:1 ratio has a sticky consistency and is easier to apply.

Made in Italy

REGENFAST® is manufactured by the traditional Italian family-owned company MASTELLI Bio-Pharmaceutical. MASTELLI looks back on more than 70 years of research in extraction of polynucleotides. The company is unique with this know-how and offers products for various therapeutic areas including dermatology, aesthetic medicine, gynecology, wound care and orthopedics.



Treatment options tailored to needs

Earn your patients' trust

What makes REGENFAST® a solution you and your patients can trust?

- > The combination of polynucleotides and hyaluronic acid has enjoyed success in medical treatments, such as skin care and orthopedics, for many years now
- > REGENFAST® has been used by leading experts in the dental field in several indications and with a follow-up period of up to 1.5 years
- > REGENFAST® is convenient to use : 97 percent of users gave the handling a score of ≥ 7 on a 1-10 scale (1=poor, 10=excellent)²
- > Based on clinical experience, treatment with REGENFAST® promotes faster and physiological repair: 98 percent of users gave the early healing a score of ≥ 7 on a 1-10 scale (1=poor, 10=excellent)²

Periodontal treatment

NON-SURGICAL TREATMENT
> **Periodontal pockets**

→ Use REGENFAST® alone

SURGICAL TREATMENT
> **Infrabony defects**
> **Furcation defects**

→ REGENFAST® can be combined with Geistlich Bio-Oss® or Geistlich Bio-Oss® Collagen



Extraction socket management

> **Ridge preservation**
> **Immediate implant placement**


→ REGENFAST® can be combined with Geistlich Bio-Oss® or Geistlich Bio-Oss® Collagen and with Geistlich Mucograft® Seal



Minor bone augmentation


> **Fenestrations around implants**
> **Dehiscences around implants**

→ REGENFAST® can be combined with Geistlich Bio-Oss® or Geistlich Bio-Oss® Collagen and with Geistlich Bio-Gide®



What makes REGENFAST® so unique?

- > REGENFAST® is an easy-to-use sterile viscoelastic gel made with polynucleotides and hyaluronic acid
- > Polynucleotides are naturally present in most cells of the body. REGENFAST® contains highly purified and completely resorbable polynucleotides, which create a hydrated and protective microenvironment that promotes cell development and vitality
- > Hyaluronic acid is an essential component of the extracellular matrix; it promotes the mechanical and elastic properties of the tissue
- > The combination of the two substances stimulates cell growth and enhances cell vitality to support the regeneration of oral tissues¹



Soft tissue regeneration

- > **Single or multiple recessions**
- > **Soft tissue augmentation**
- > **Gain of keratinized tissue**

→ REGENFAST® can be combined with Geistlich Fibro-Gide® or Geistlich Mucograft®



Major bone augmentation

- > **Horizontal defects**
- > **Vertical defects**
- > **Combined horizontal/vertical defects**
- > **Bone deficiency after resolved peri-implantitis**

→ REGENFAST® can be combined with Yxoss Customized Bone Regeneration (CBR)®, Geistlich Bio-Oss® and with Geistlich Bio-Gide®





Supporting more efficient repair!¹

More than 700 patients have been treated with REGENFAST® in Europe to date. The following treatment advice stems from leading experts who have used REGENFAST® alone or in combination with autogenous tissue or Geistlich biomaterials in different indications and with a follow-up time of up to 1.5 years.



Tips & tricks from leading experts based on their experience with REGENFAST®



Periodontal treatment

NON-SURGICAL PERIODONTAL TREATMENT

- > REGENFAST® can be used on its own for periodontal pockets after periodontal retreatment with curettes and after ultrasonic instrumentation.
- > REGENFAST® is not suitable as an anti-inflammatory treatment and is only intended to be used after the underlying cause of the periodontal pocket has been resolved.
- > **It's best to use an 18 G blunt tip syringe around 10 mm long.**

SURGICAL PERIODONTAL TREATMENT

- > REGENFAST® can be used on its own for contained infrabony defects.
- > For non-contained defects, REGENFAST® can be combined with Geistlich Bio-Oss® or Geistlich Bio-Oss® Collagen.
- > The affected site does not require preparation with pre-treatment preparation.
- > After root debridement, place a few drops of REGENFAST® at the bottom of the defect at root level, then add Geistlich Bio-Oss® pre-mixed with REGENFAST® at a maximum ratio of 3:1 (Geistlich Bio-Oss®:REGENFAST®).
- > Always distribute the remaining REGENFAST® on the suture lines to improve healing.
- > **It's best to use an 18 G blunt tip syringe around 10 mm long.**



Single and multiple recessions

- > The treatment of gingival recessions can be improved either by using REGENFAST® on its own, or in combination with a connective tissue graft or collagen matrices (preferably Geistlich Fibro-Gide®).
- > Apply REGENFAST® to the matrix and wait a few minutes for Geistlich Fibro-Gide® to be fully soaked before placing it in the treatment site.
- > REGENFAST® can also be applied to both sides of the matrix after it has been sutured inside the treatment site.
- > If Geistlich Mucograft® is being used to treat recessions or to widen the band of keratinised tissue, it must be soaked in situ in order to avoid delaminating the matrix.
- > Coronally advanced flap is the suggested technique, but tunnel is also possible.
- > Always distribute the remaining REGENFAST® on the suture lines to improve healing.
- > **A syringe tip is not strictly necessary but can help avoid losing unnecessary amounts of REGENFAST®.**
- > **In this case, use a short 30 G tip.**



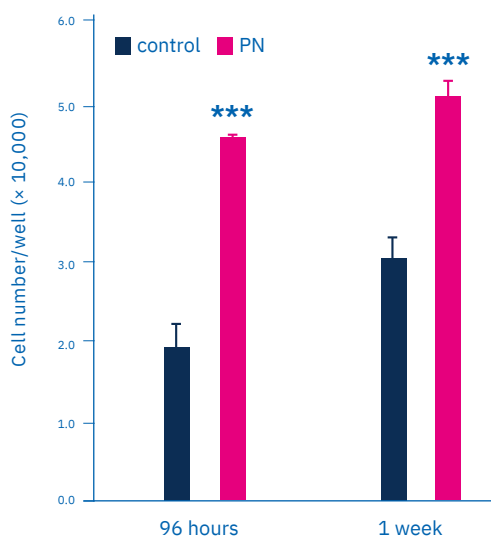
Bone regeneration

- > For treatment of extraction sockets, minor and major bone defects REGENFAST® can be added directly to Geistlich Bio-Oss® using a maximum ratio of 3:1 (Geistlich Bio-Oss®:REGENFAST®). Don't wet Geistlich Bio-Oss® with saline but only with REGENFAST® in order to not dilute it.
- > Add REGENFAST® drop by drop to make the most of its regenerative potential and viscoelastic properties.
- > When combining REGENFAST® with a mixture of Geistlich Bio-Oss® and autologous bone, the ratio can even be decreased due to the presence of inductive factors and blood.
- > Geistlich Bio-Oss® Collagen can be combined with REGENFAST® either before or after it has been placed in the site.
- > When applying REGENFAST® before, add a sufficient amount to the biomaterial and wait a few minutes for it to fully soak.
- > When adding REGENFAST® after Geistlich Bio-Oss® Collagen has been placed in the site, soak the block with a few drops of saline, insert it into the defect, then apply REGENFAST®.
- > Finish up by soaking Geistlich Bio-Gide® once it has been positioned to cover the defect.
- > Always distribute the remaining REGENFAST® on the suture lines to improve healing.
- > **A syringe tip is not strictly necessary but can help avoid losing unnecessary amounts of REGENFAST®.**
- > **In this case, use a short 30 G tip.**

The science behind REGENFAST®

Preclinical study:
Polynucleotide gel
enhances tissue
repair, matrix
deposition and
organization³

Polynucleotides (PN) improve the
growth of human fibroblasts in vitro



Study results

IN VITRO

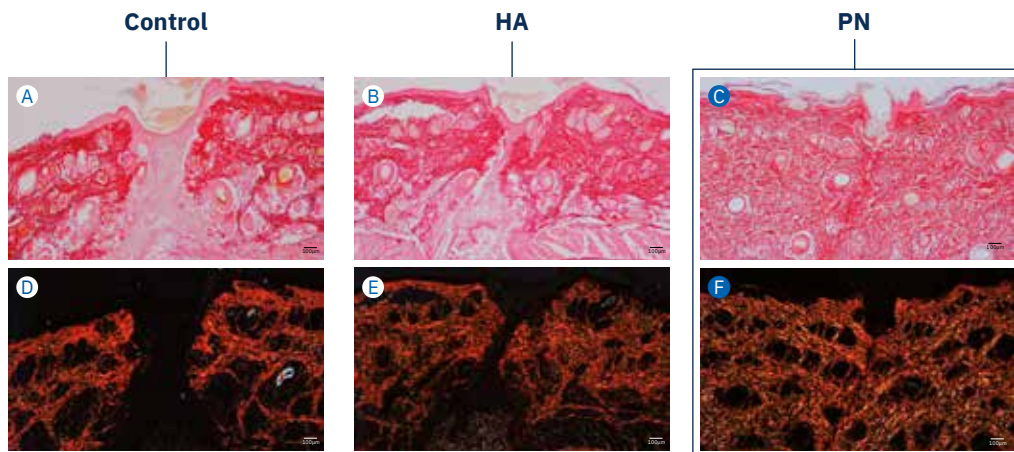
> Addition of PN to cell medium enhanced fibroblast growth and their viability. PN promoted wound healing as measured by scratch assay.

IN VIVO

> PN-treated tissues present a mature extracellular matrix, with well-organized collagen fibers that have almost completely bridged the surgically-created wound.

> The animal study confirmed that PN create an environment that favors collagen deposition and indirectly promote its prompt recovery, without showing signs of fibrosis.

Microphotography of healing wounds in the control (A), with Hyaluronic Acid (HA) (B), with Polynucleotides (PN) (C), after Sirius Red staining for the collagen using transmitted (A,B,C) or polarized light (D,E,F). (A,D): The defect is still devoid of collagen fibers. (B,E): The collagen fibers only partially occupy the healing tissue area. (C,F): The wounds are almost completely healed, and collagen fibers appear mature and well organized in comparison to control and Hyaluronic Acid.

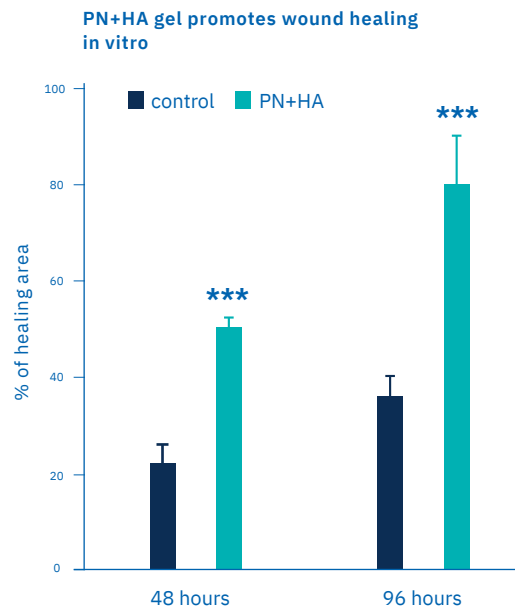


control = culture medium

1 REGENFAST® – Instructions for Use.
2 Data on file. Geistlich Pharma AG
3 Colangelo M et al., Journal of Biological Regulators and Homeostatic Agents. 2021 Jan-Feb;35(1):355-362. doi: 10.23812/20-320-L.

4 Colangelo M et al., Applied Sciences. 2021; 11(10):4405. doi: 10.3390/app11104405.
5 Pilloni A. et al., Journal of Periodontology, 2022 Oct 3. doi: 10.1002/JPER.22-0225.
*** p-value ≤ 0.001

Preclinical study:
Gel with poly-
nucleotides and
hyaluronic acid
promotes wound
healing⁴



Study results

IN VITRO

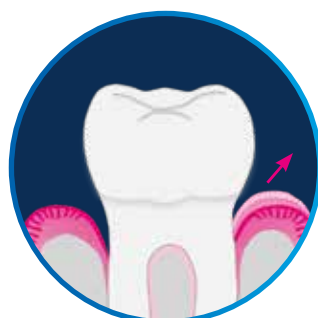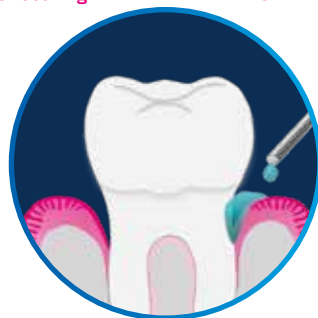
- > In a scratch assay, PN+HA achieved gap closure after 48 hours, while cells in the comparison groups had not bridged the scratch even after 96 hours.
- > PN+HA is a promising candidate for supportive therapy to promote soft tissue healing in the oral cavity.

Clinical study:
Proven efficacy
and safety of
REGENFAST®
(PN+HA gel)
in non-surgical
periodontal
therapy⁵

Split mouth model

No additional treatment
after scaling

Scaling +
REGENFAST®



Study results

- > PN+HA gel promoted superior results in terms of probing depth (PD) reduction; at 48 weeks, there were more sites with PD ≤ 4 mm in the test vs. control group.
- > Significantly higher reduction in modified sulcular bleeding index in the test group.
- > Non-surgical re-instrumentation with the adjunctive use of a PN+HA gel helped to reduce the clinical parameters of inflammation in deep periodontal pockets.

GBR with REGENFAST®: Preliminary histological features



Prof. Claudia Dellavia
Milano, Italy

New strategies are being developed to accelerate bone maturation of augmented alveolar ridges. Recently, a mixture of demineralized bovine bone particles (Geistlich Bio-Oss®) with a combination of polynucleotides and hyaluronic acid (REGENFAST®) has been proposed for vertical/horizontal alveolar bone regeneration in partially edentulous patients. Preliminary clinical data appear to be promising. Histological and histomorphometric data are essential to evaluate the regeneration process in terms of quality and quantity of the newly formed tissue. Bioptical specimens were retrieved during implant placement about 6 months after Guided Bone Regeneration (GBR) and processed for histological analysis without prior decalcification.

Evidence from the first samples (Fig. 1) shows the formation of highly mineralized and well-organized viable new bone, totally incorporating the biomaterial remnants. Several residual granules can be observed in close contact with the regenerated bone which appears to stratify at the edges of the fragments with many osteoblastic-like cells lining the borders of bone regeneration.

In most areas, tissue maturation seems to be at an advanced stage, with the lamellar aspect prevailing over the woven bone features. The osteoid matrix is minimal when considering the initial time of surgical re-entry. The ground sections analyzed showed only a few resorption lacunae, while the deposition activity is clearly evident. The medullary

spaces filled with numerous large blood vessels, were populated by many cells but were free of inflammatory infiltrate. Preliminary conclusion: the current histological characteristics may suggest the formation of a significant amount of new vital bone in the phase of physiological remodeling and perfectly osseointegrating the grafted particles. Further clinical studies will investigate the clinical benefits of adding REGENFAST® to Geistlich Bio-Oss® for Guided Bone Regeneration in more detail, for example focusing on the question if addition of REGENFAST® accelerates bone regeneration and allows for an earlier implant placement.

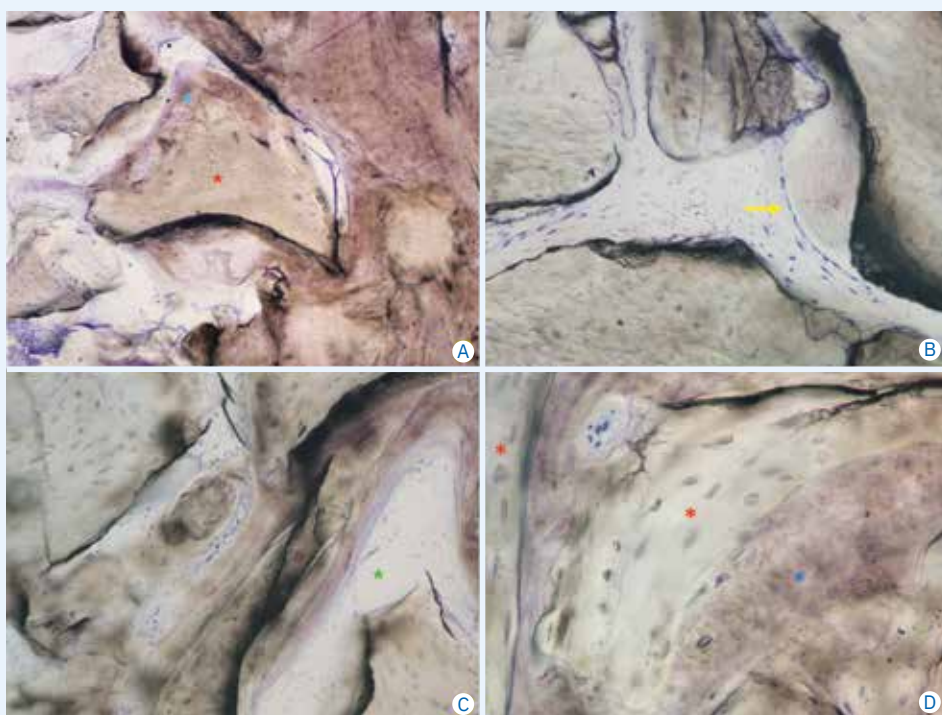


Fig. 1. Undecalcified histological sections from sites regenerated with Geistlich Bio-Oss® and REGENFAST® mixture at 6 months. Toluidine Blue and Pyronin Yellow staining. Total magnification: A) 100x; B) 200x; C) 200x; D) 400x. In blue: osteoid and cells, in purple: tissue in phase of mineralization, in brown: Geistlich Bio-Oss® and highly mineralized bone. Red asterisks indicate residual grafted particles; blue asterisks depict areas of regenerated bone; green asterisk shows blood vessels in the marrow spaces; yellow arrow indicates a front of osteoblast-like cells (the samples were taken during surgeries performed by Dr. Mario Beretta, Dr. David Palombo and Dr. Federico Rivara).

Treatment of a patient with generalized periodontitis



Dr. Roberto Rotundo
Florence, Italy

Case captions:

1 A–C Clinical and radiologic situation before treatment | **2** The diagram shows the deep pockets and high bleeding on probing scores: Mean probing depth 5.7 mm, mean attachment level -5.9 mm, 53% plaque, 88% bleeding on probing | **3** Application of REGENFAST® | **4 A–C** Clinical and radiologic situation after 6 months | **5** The diagram shows the measurements 6 months after the treatment: mean probing depth 3.4 mm, mean attachment level -4.8 mm, 11% plaque, 34% bleeding on probing (mean pocket depth reduction: 2.3 mm, mean attachment level gain: 1.1 mm, mean plaque reduction: 42%, mean bleeding on probing reduction: 54%).

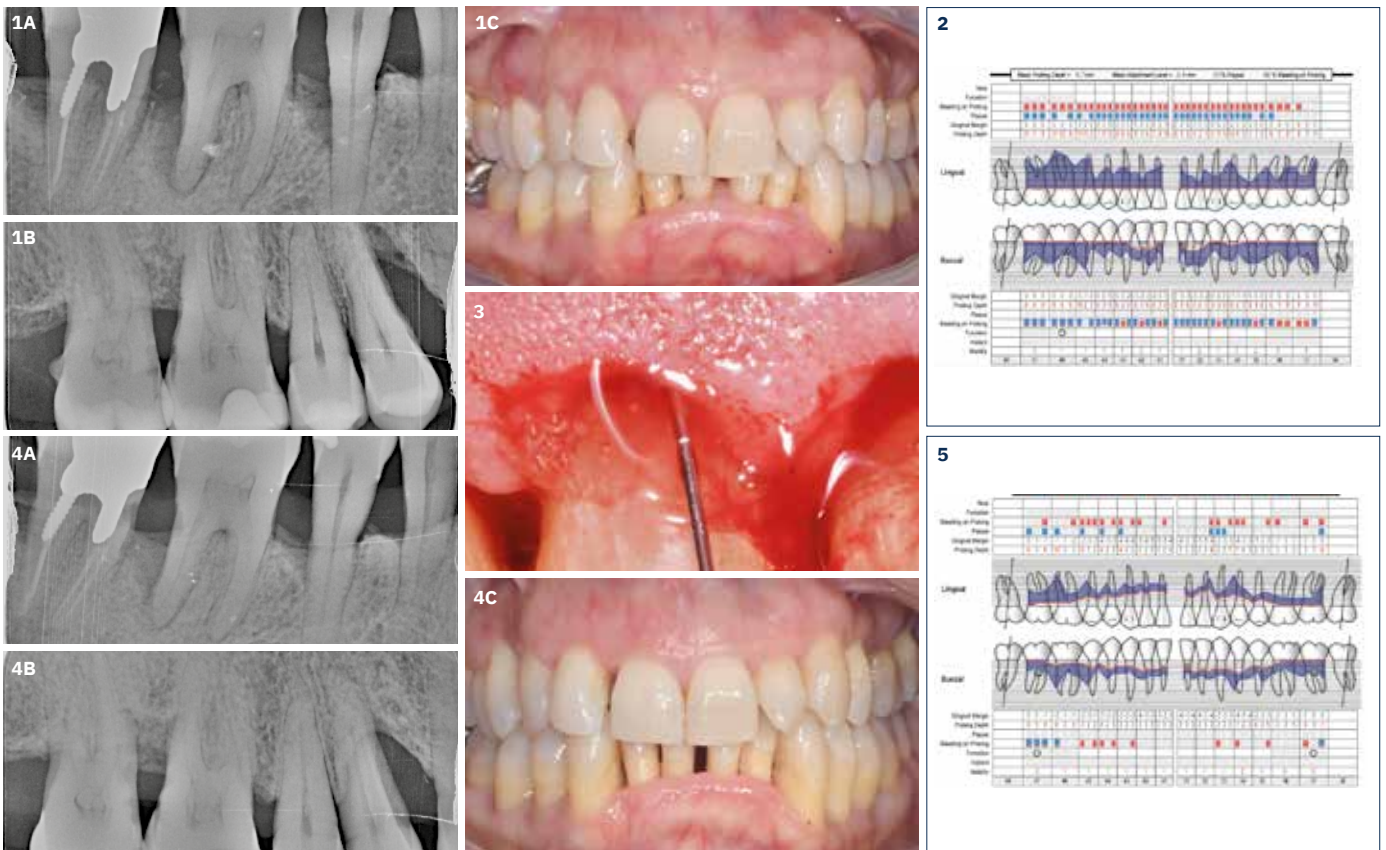
Case description:

The patient (49 years old, female, non-smoker, no medical history) was affected by stage 3, grade C periodontitis and referred for periodontal treatment. Presence of both horizontal and vertical bone resorption (>2 mm) in correspondence of tooth 14, 24, 26, 27, 34, 35, 36, 45, 46. Tissue phenotype: >1 mm.

Why did I use REGENFAST®?



The angiogenic and metabolic potential of hyaluronic acid associated with polynucleotides on periodontal tissues seems to show interesting clinical outcomes. A wide impact on the population affected by periodontitis may be obtained by combining this product with conventional mechanical non-surgical therapy.



Treatment of an infrabony defect in the distal mandible



Dr. Roberto Abundo
Torino, Italy



Why did I use REGENFAST®?

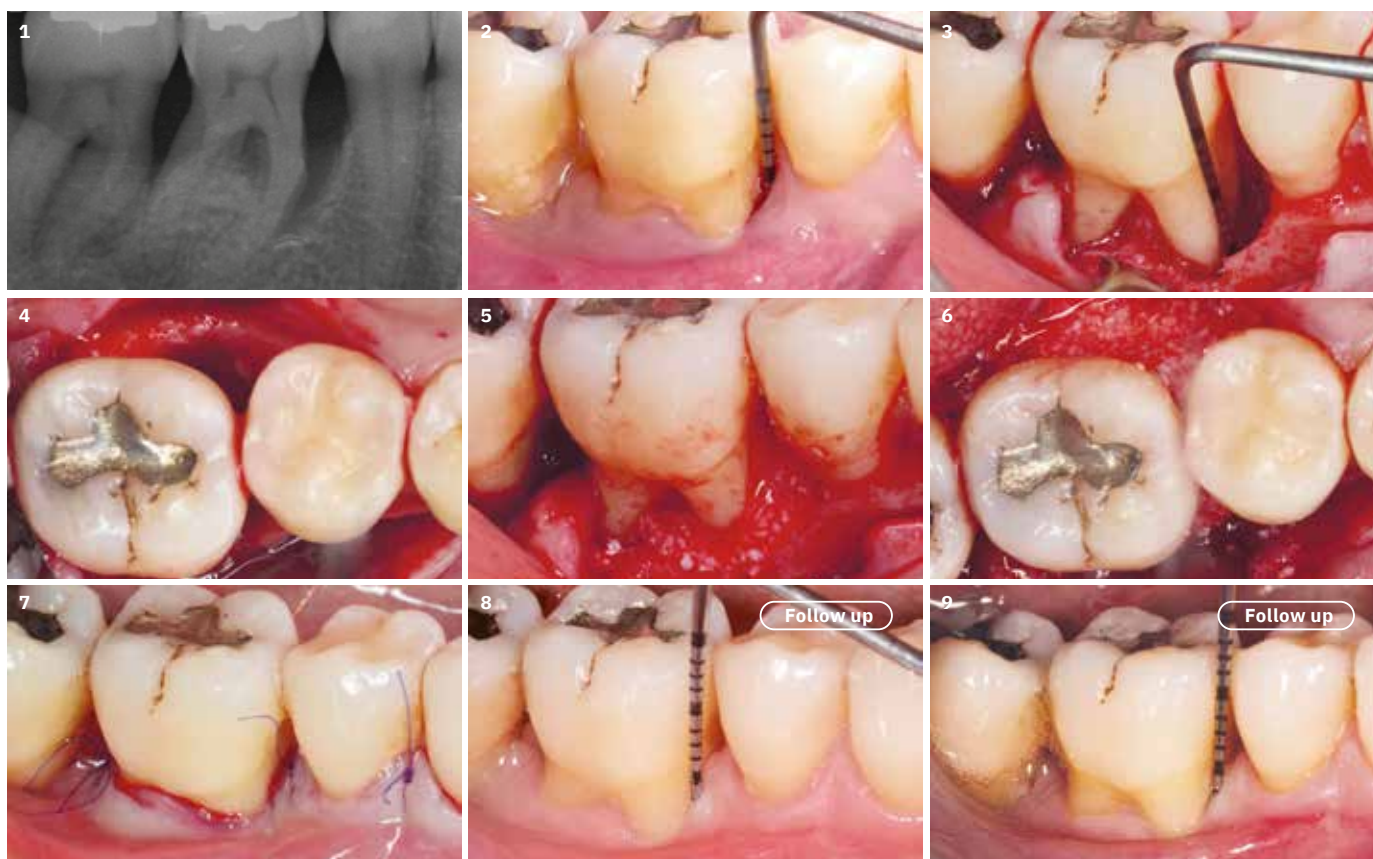
I used REGENFAST® in addition to Geistlich Bio-Oss® because I think, in the healing of GTR procedures, the principle “the sooner, the better” is effective for achieving optimal results.

Case description:

A patient with stage 3, grade C periodontitis was treated. After completion of non-surgical anti-infective therapy there was a residual deep infrabony pocket on tooth 46. Guided Tissue Regeneration with Geistlich Bio-Oss® and REGENFAST® was performed with an excellent outcome.

Case captions:

1 Radiographic image before treatment | **2** Pocket depth before treatment (9 mm) | **3** Intraoperative view of the infrabony defect | **4** Intraoperative occlusal view of the infrabony defect | **5** Defect filled with a mix of Geistlich Bio-Oss® and REGENFAST® | **6** Occlusal view of defect filled with a mix of Geistlich Bio-Oss® and REGENFAST® | **7** Wound closure | **8** Pocket depth 6 months after treatment (4 mm) | **9** Pocket depth 12 months after the treatment (4 mm).



Treatment of an infrabony defect in the anterior maxilla

Prof. Francesco Cairo
Florence, Italy



Case captions:

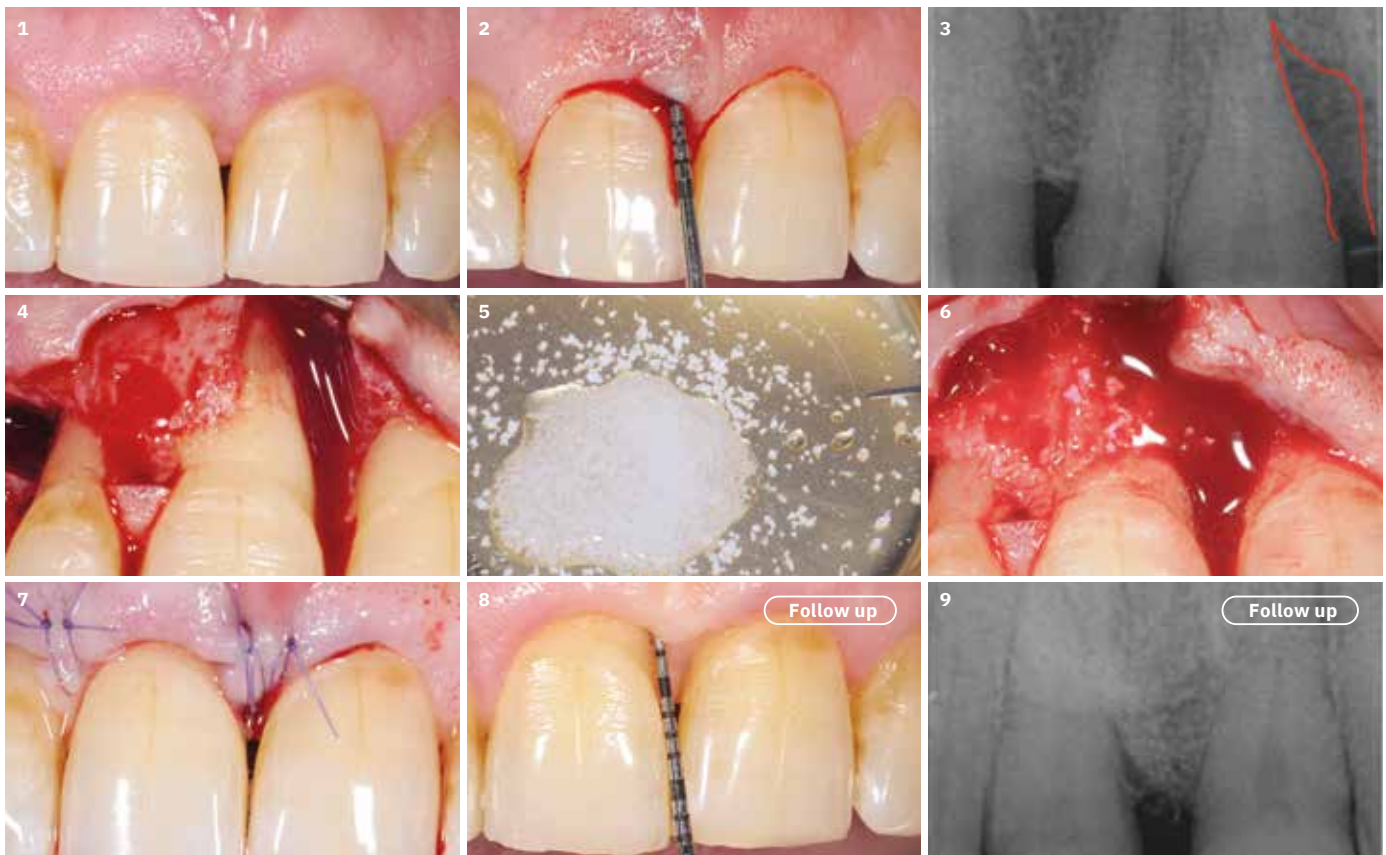
1 Soft-tissue situation at baseline. | **2** Bleeding on probing | **3** A deep infra-bony defect is detected (red line) adjacent to the left central upper incisor | **4** Flap surgery with simplified papilla preservation flap. A deep non-contained two-wall defect is visible | **5** A mix of Geistlich Bio-Oss® and REGENFAST® is prepared | **6** After gentle root cleaning, REGENFAST® is applied on the root. Then, the mixture of REGENFAST® and Geistlich Bio-Oss® is applied on the defect | **7** Primary wound closure is obtained with 6-0 PGA sutures | **8** One year after surgery, the final probing depth is minimal, and the recession is reduced to 1 mm | **9** The X-ray one year after surgery shows very good resolution of the defect.

Case description:

The patient (65 years old, male, non-smoker) showed generalized periodontitis of stage IV, grade C. After causal therapy, regenerative periodontal surgery with Geistlich Bio-Oss® and REGENFAST® was planned for residual pockets.

Why did I use REGENFAST®?

REGENFAST® promotes a fast healing process after periodontal reconstructive surgery.



Treatment of an infrabony defect in the maxillary front area



Dr. Raffaele Cavalcanti
Bari, Italy



Why did I use REGENFAST®?

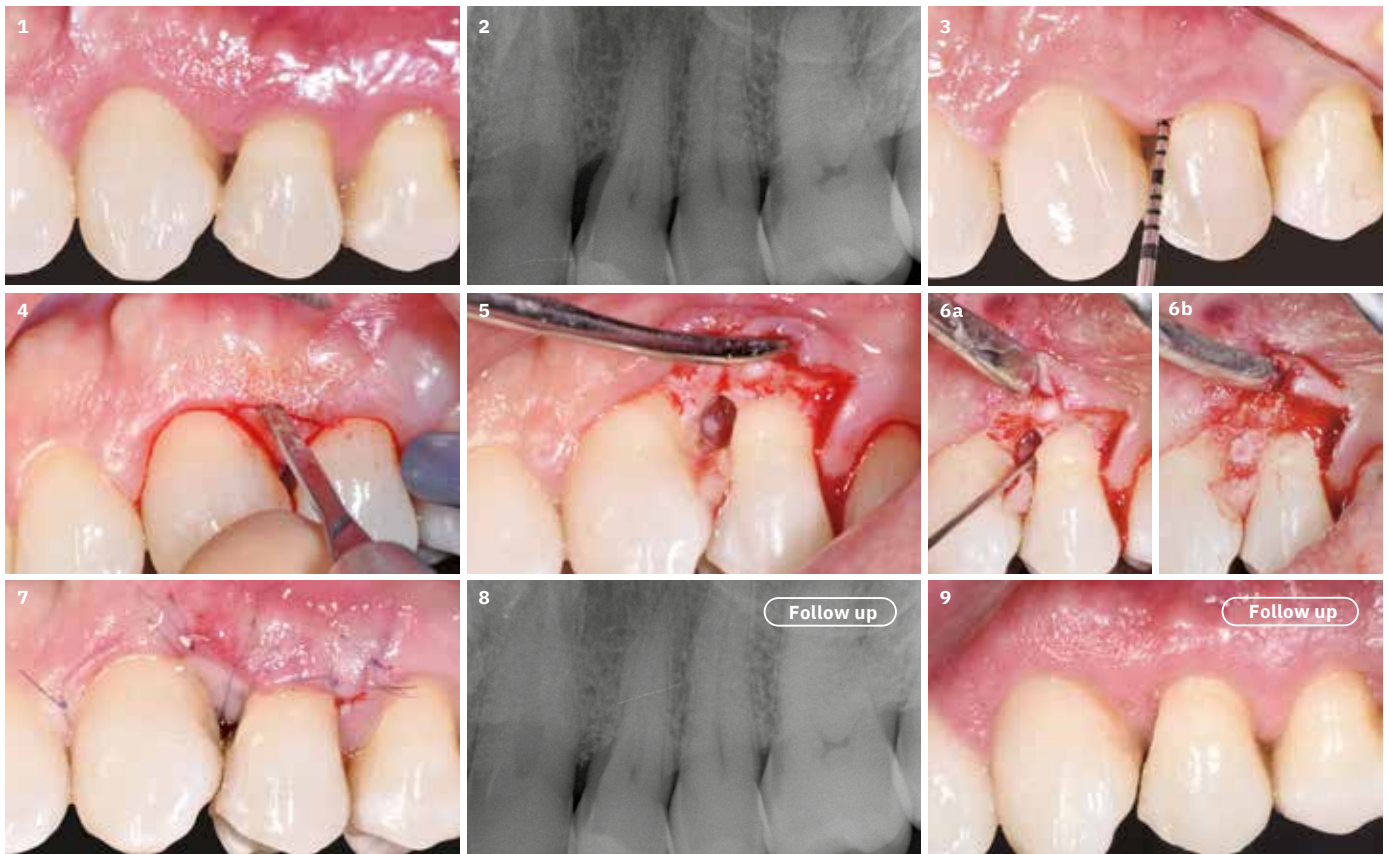
The need for a biological mediator to promote and enhance post-surgery healing process is a scientifically supported issue. REGENFAST® polynucleotides gel is at the same time easy to handle and to apply and guarantees a true boost to the regenerative processes.

Case description:

The patient (45 years old, no systemic diseases, non-smoker) still had a deep periodontal pocket (7 mm) after cause-related periodontal therapy. Regenerative periodontal surgery was performed by means of modified papilla preservation technique (MPPT) and M-MIST flap elevation.

Case captions:

1 Baseline clinical image. | **2** Baseline x-ray with visible vertical osseous defect. | **3** Probing pocket depth of 7 mm after causal therapy. | **4** Modified papilla preservation technique incision. | **5** Minimal flap elevation (M-MIST). | **6** After defect debridement and gentle root planning, REGENFAST® was applied to the root surface and the infrabony component was filled with Geistlich Bio-Oss®. | **7** End of surgery with suture. | **8** 18 months x-ray follow-up. | **9** 18 months clinical follow-up.



Treatment of a premolar periodontal defect located in the furcation area

Dr. Philippe Doucet
Paris, France



Case captions:

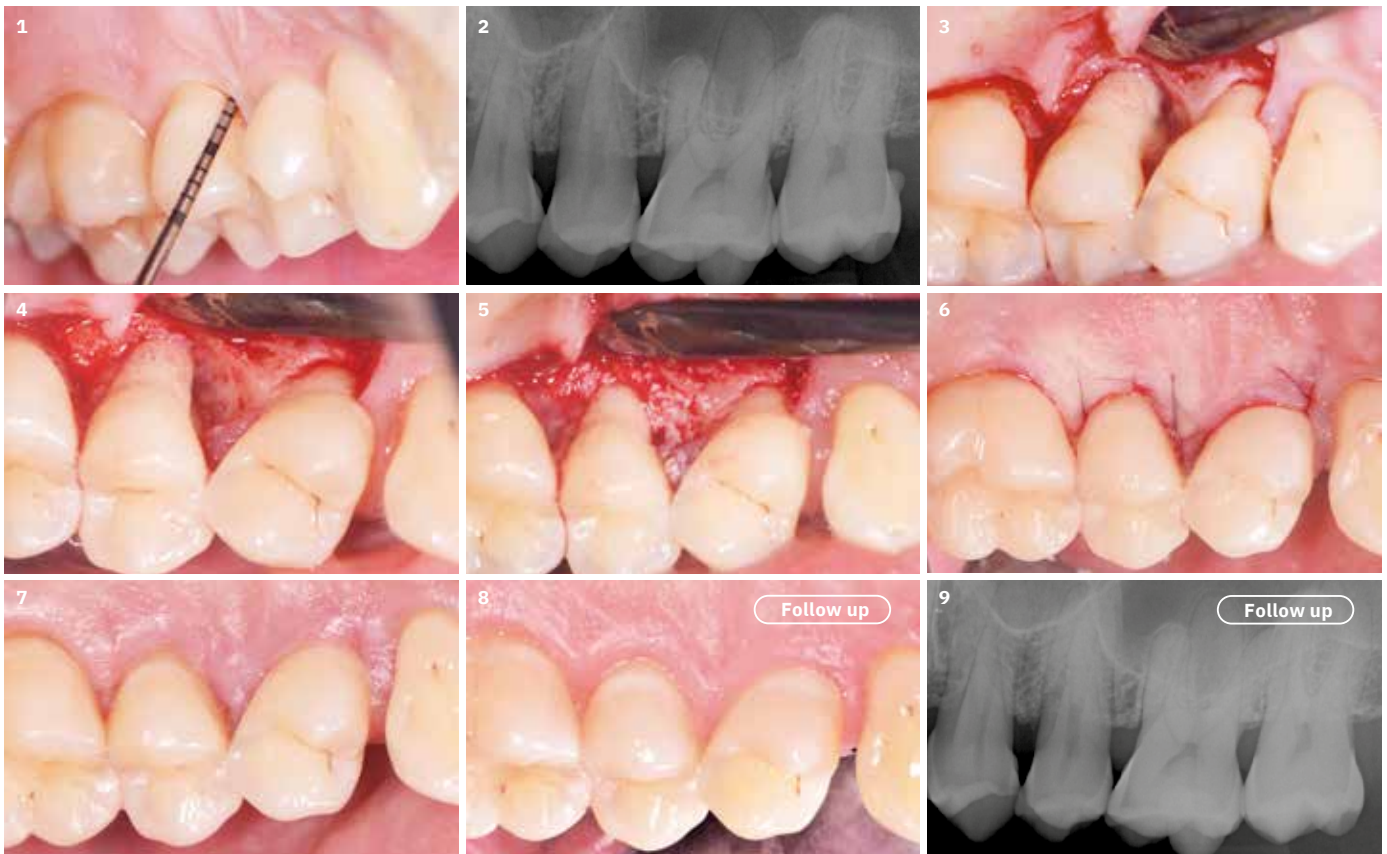1 Palatal view of tooth 25. A 6 mm probing pocket depth is present with associated bleeding. | **2** An infrabony defect is visible on the X-ray, mesial to tooth 25, at the level of the furcation | **3** Realization of a palatal full-thickness flap with a 3 mm mesial releasing incision and preservation of the papillae. Debridement of the lesion and visualization of the intraosseous defect reaching the furcation zone. | **4** The papilla located at the level of the defect is completely preserved and not elevated. | **5** A mixture of Geistlich Bio-Oss® and REGENFAST® is placed in the defect. | **6** Vertical mattress sutures are realized at the level of the papilla. | **7** Suture removal at 15 days post-op. | **8** Palatal clinical view at 6 months | **9** Retroalveolar X-ray at 6 months.

Case description:

A 46-year old patient received an initial periodontal therapy. Because of persistent pockets with bleeding on probing associated with intra-osseous defects on teeth 25, 42 and 43, these sites were selected for regenerative periodontal surgery.

Why did I use REGENFAST®?

I decided to use REGENFAST® in periodontal regeneration because its components, polynucleotides and hyaluronic acid, have interesting properties in different tissue regeneration procedures. Above all, I particularly appreciate the product's ability to promote rapid wound healing, which is a key point in periodontal regeneration.



Multiple recession coverage in the anterior maxilla



Prof. Daniele Cardaropoli
Torino, Italy



Why did I use REGENFAST®?

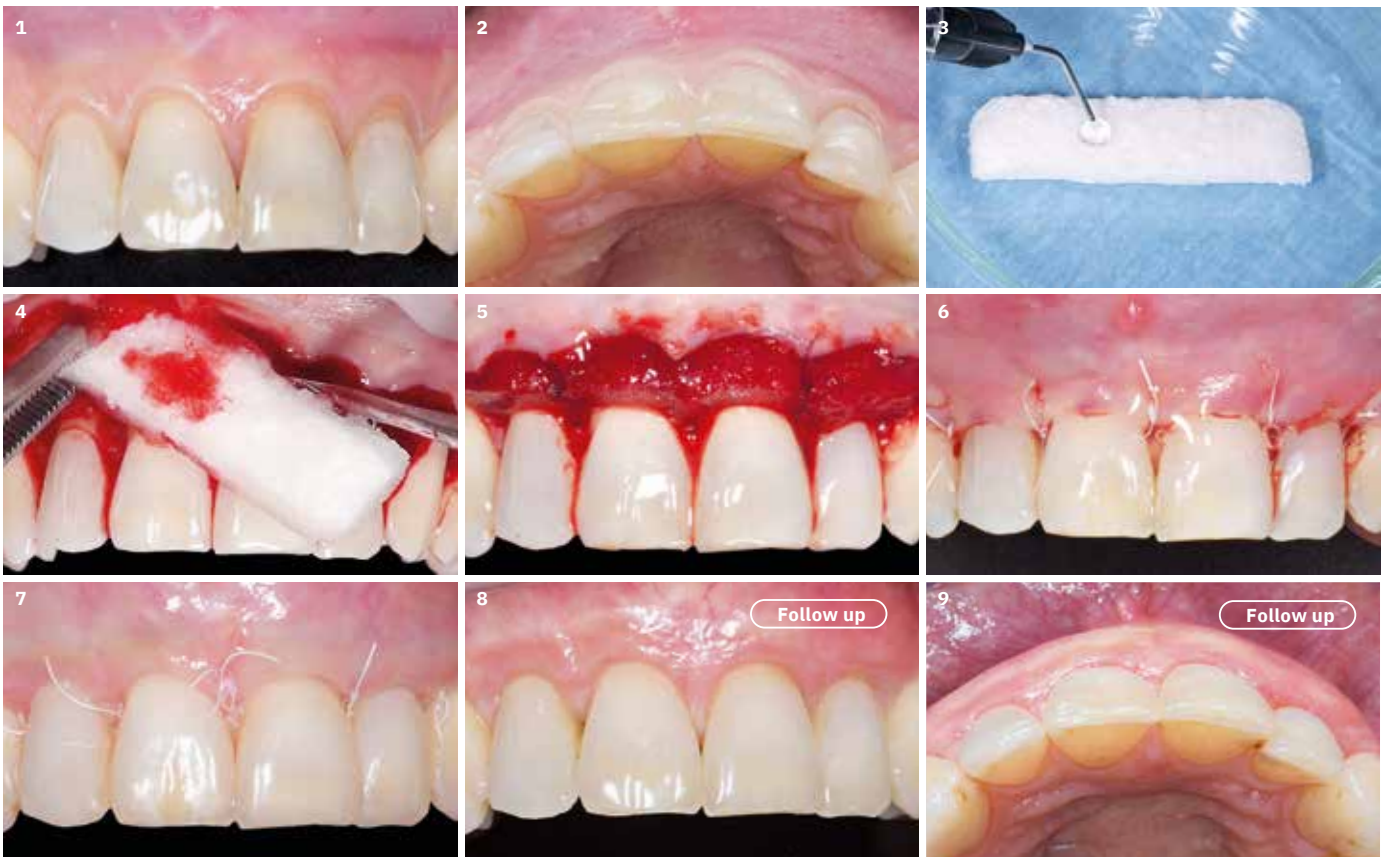
Whenever possible, I always try to use biological mediators that can positively influence wound healing. REGENFAST® is an excellent adjuvant in periodontal plastic surgery procedures in this regard.

Case description:

The patient (56 years old, systemically healthy, non-smoker) came with an esthetic request related to gingival recessions in the maxillary front region as well as dental sensitivity. Multiple recessions were found many of which were associated with enamel abrasions.

Case captions:

- 1 Initial situation, frontal view with multiple recessions visible.
- 2 Initial situation. The occlusal view highlights the need to increase the soft tissue thickness.
- 3 Geistlich Fibro-Gide® (thickness 3 mm) is soaked with REGENFAST®.
- 4 Preparation of the flap with adequate passivation.
- 5 Geistlich Fibro-Gide® is placed and sutured to the recipient bed.
- 6 The flap is advanced coronally and sutured without tension.
- 7 On removal of the sutures after two weeks, the tissues already show excellent healing.
- 8 Situation 6 months after surgery, frontal view.
- 9 Situation 6 months after surgery, occlusal view.



Multiple recession coverage in the anterior maxilla



Dr. Federico Rivara
Mantova, Italy

Case captions:

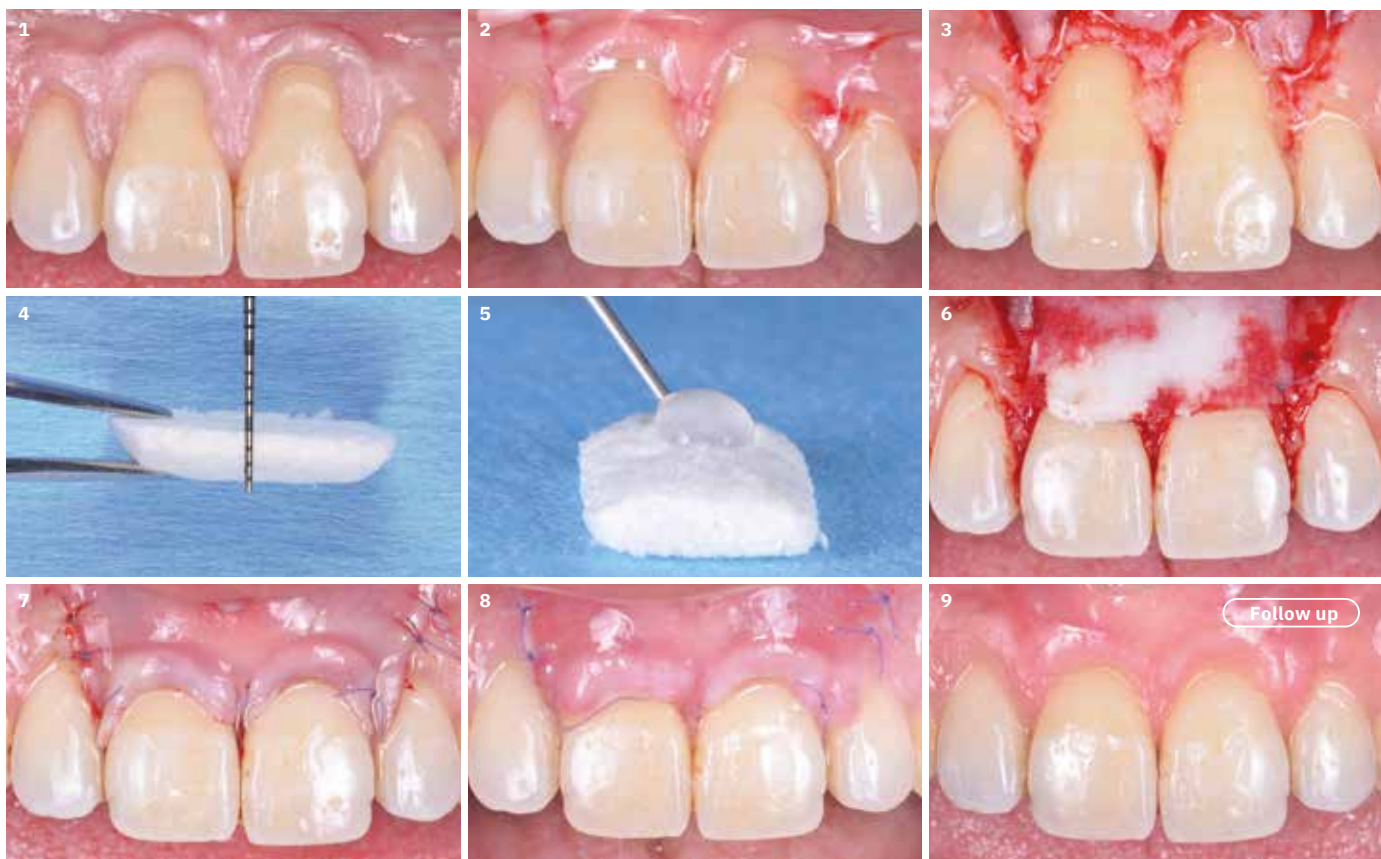1 Initial situation: teeth 11 and 21 present with gingival recession, root abrasion and preserved cement-enamel junction. | **2** Flap design for coronally advanced flap. | **3** Split-full-split thickness flap, the anatomical papillae are de-epithelized. The roots are smoothed with curettes. | **4** Geistlich Fibro-Gide® is shaped. | **5** REGENFAST® is applied on the matrix until it is soaked. | **6** Geistlich Fibro-Gide® is fixated with polyglycolic acid 6-0 sutures. | **7** The flap is released with superficial and deep incisions on the inner side, and sutured. Vertical incisions are sutured with single stitches. | **8** 14-day check, the situation is stable. | **9** Follow-up at 6 months. The soft tissue situation is stable. The root coverage is complete.

Case description:

A patient (44 years old, male, pipe smoker once a day) with gingival recessions RT-1 on upper central incisors with intact enamel-cement junction. Recession coverage surgery was performed in combination with Geistlich Fibro-Gide®.

Why did I use REGENFAST®?

I decided to use Geistlich Fibro-Gide® to achieve root coverage in the presence of root abrasions. REGENFAST® in this case played a role in improving soft-tissue healing in particular in the early phase when the stability of the wound is crucial for the success of the treatment.



Phenotype thickening of class I multiple recessions



Dr. Jonathan Semtob
Paris, France



Why did I use REGENFAST®?

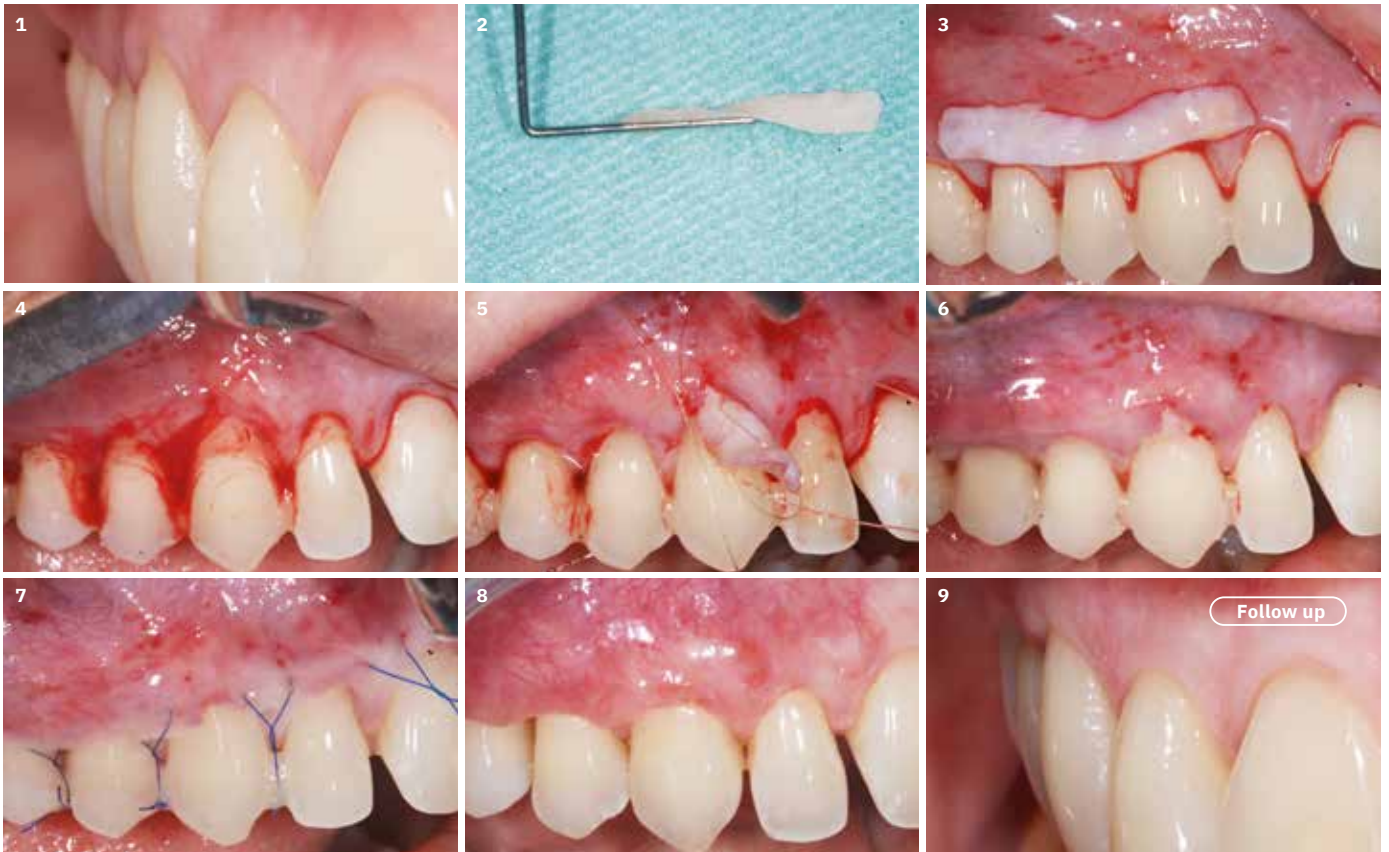REGENFAST® was used to promote blood clot stability and wound healing. It could be applied on bleeding tissues and was quite compatible with an injection under a tunneled flap. Also, the application procedure was fast and comfortable for the patient and the operator.

Case description:

The patient (40 years old, female, non-smoker) presented with gingival sensitivities, bleeding when brushing, and slight recessions. To thicken the gingival phenotype, soft-tissue augmentation was planned in conjunction with REGENFAST®.

Case captions:

1 Pre-operative situation: Miller class I multiple gingival recession on teeth 11 to 14, 1-2 mm depth. Sufficient keratinized tissue height.
2 Extraoral de-epithelialized free gingival graft: 1 mm thickness
3 Connective tissue graft lying on the tunneled flap. | **4** REGENFAST® injected inside the tunneled flap and on the roots | **5** Connective tissue inserted under the flap by two mattress sutures, one on each graft extremity | **6** Connective tissue positioned at the cemento-enamel junction on the canine | **7** Horizontal suspended sutures advancing the flap coronally. Graft totally covered by the flap.
8 At 15 days post-operatively, a complete root coverage was obtained for all the treated recessions. The esthetic integration is already satisfactory. | **9** At 6 months post-operatively, the gingival thickness obtained shows more resistance to tooth brushing.



Localized root coverage with a modified tunneling technique



Dr. Marco Zeltner
Zurich, Switzerland

Case captions:

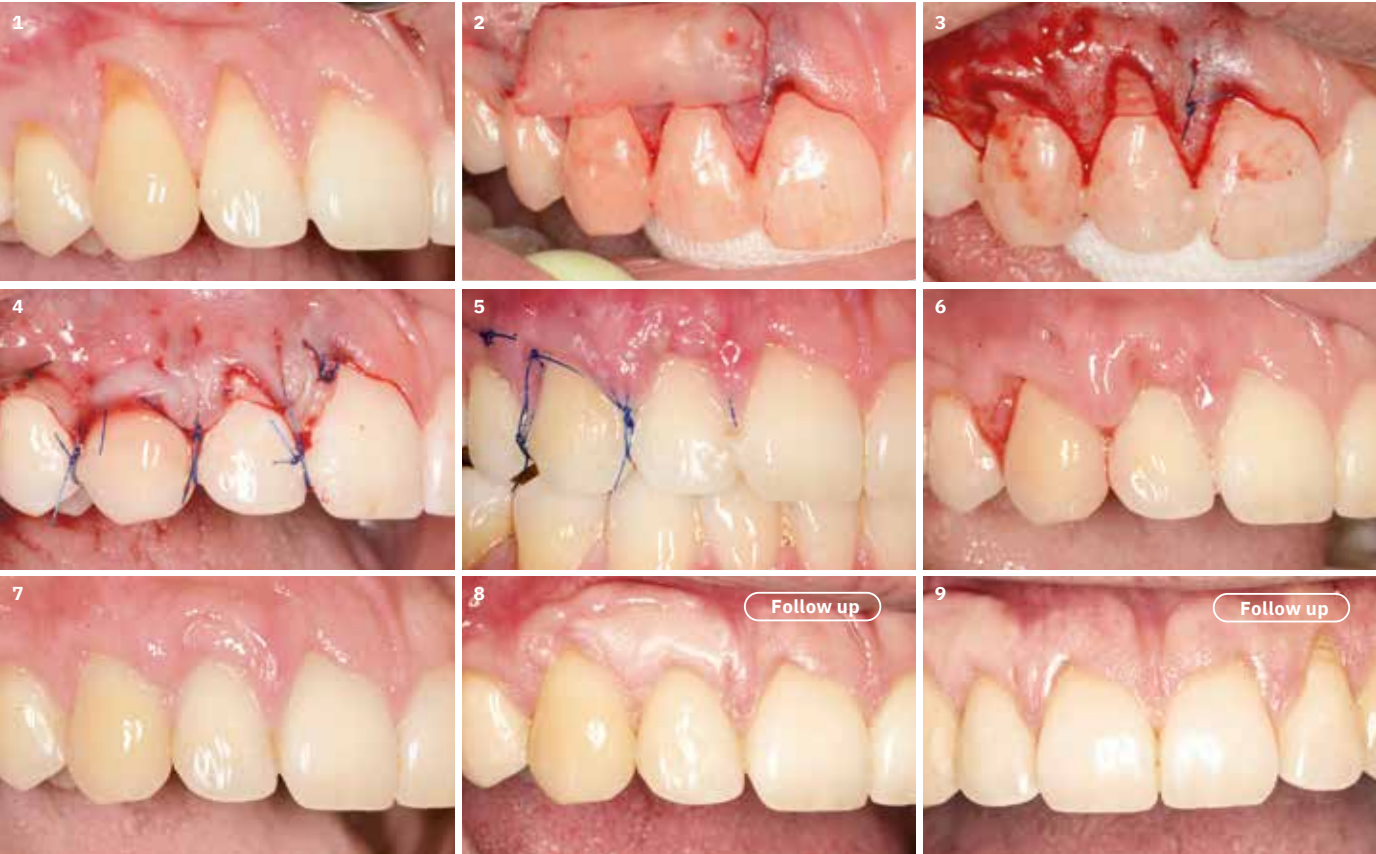- | 1 Clinical situation at baseline.
- | 2 Dimensions of the autogenous connective tissue graft.
- | 3 Insertion of connective tissue graft into the tunnel.
- | 4 Coronal advancement of the flap using vertical sling sutures.
- | 5 Clinical situation 10 days after surgery.
- | 6 Clinical situation after suture removal.
- | 7 Clinical situation 1 month after surgery.
- | 8 Clinical situation 1 year after surgery.
- | 9 The clinical situation 1 year after surgery shows complete coverage of the recessions.

Case description:

The patient (43 years old, male, non-smoker) showed proceeding localized recessions in the esthetic area. Root coverage was planned with a modified tunneling technique and an autogenous connective tissue graft from the palate.

Why did I use REGENFAST®?

REGENFAST® was used to promote wound healing at the recipient site. Additionally, it was also applied to the donor site to accelerate healing and reduce the patient’s post-operative discomfort and morbidity.



Modified Strip Technique after bone augmentation in the distal maxilla



Dr. Sébastien Monlezun
Bordeaux, France



Why did I use REGENFAST®?

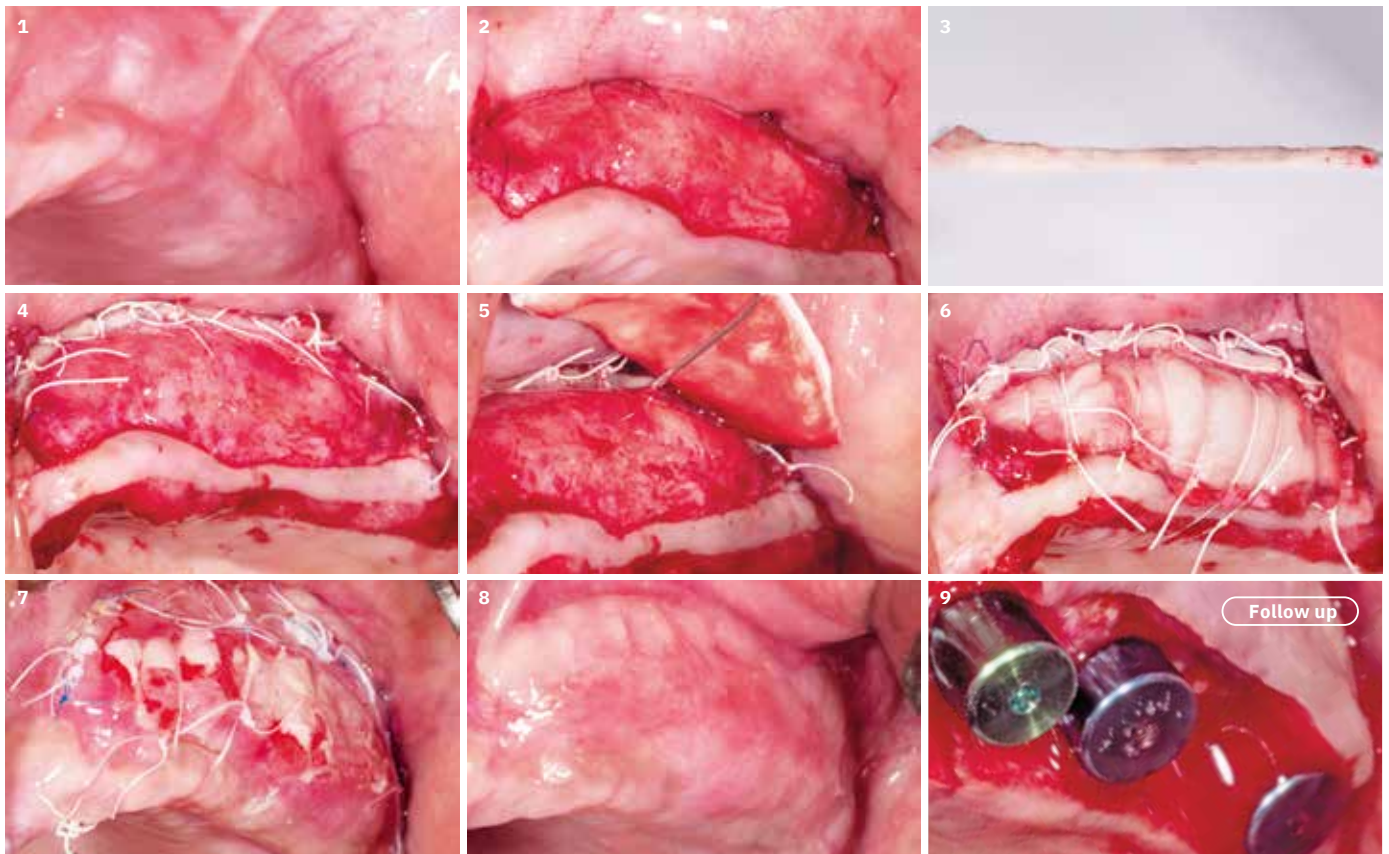
REGENFAST® is a precious help, especially for the most demanding muco-gingival cases around teeth and implants. Healing is incredibly fast. That's probably why patients report less post-operative pain. On top of that, it is very easy to use.

Case description:

This patient with severe bone resorption had been treated 4 months previously with Guided Bone Regeneration plus lateral sinus lift. At that time, to ensure primary healing, flaps were over-released, and the consequence was a shallow vestibule and mobile mucosa on the regenerated crest that needed to be corrected before implant placement.

Case captions:

1 4 months after bone augmentation using the Sausage Technique™, the soft-tissue situation has to be improved. | **2** Incision on the crest to raise a split thickness flap. | **3** Free gingival strip graft | **4** The strip is stabilized with 6-0 monofilament sutures. Horizontal mattress sutures (PTFE4-0) are used to anchor the strip to the periosteum. | **5** REGENFAST® is applied on the recipient bed and Geistlich Mucograft® is cut and adapted to the site above REGENFAST®. | **6** Geistlich Mucograft® is stabilized onto the site. Sutures and surgical area are then covered with REGENFAST®. | **7** Suture removal at 10 days except resorbable sutures. Soft-tissue healing is fast with low inflammation. The harvesting site is already healed. | **8** Healing at 40 days. The result is very satisfying. We now have a large band of dense, attached immobile tissue on the regenerated crest with a deep vestibule. | **9** Implant placement at 6 weeks post op.



Ridge reconstruction before implant placement



Dr. Federico Rivara
Mantova, Italy

Case captions:

1 Initial situation: the tooth has been treated endodontically without success. | **2** The buccal bone is not intact. | **3** Geistlich Bio-Oss® mixed with REGENFAST® is applied. Geistlich Bio-Gide® Compressed is rebuted vestibular and soaked with REGENFAST®. | **4** The flap is repositioned in its initial position with 5-0 polyamide sutures, leaving the membrane to heal occlusally by second intention. | **5** After 5 months, the situation is stable and the keratinized tissue is restored. | **6** An intermediate abutment is placed at the time of implant insertion. | **7** The flap is moved vestibular and sutured. | **8** At the control at 12 months, the papillae are preserved, and the proportion of keratinized tissue is ideal. | **9** The stability of the hard tissue is visible both with the 2D examination and at the 3D level (12 months).

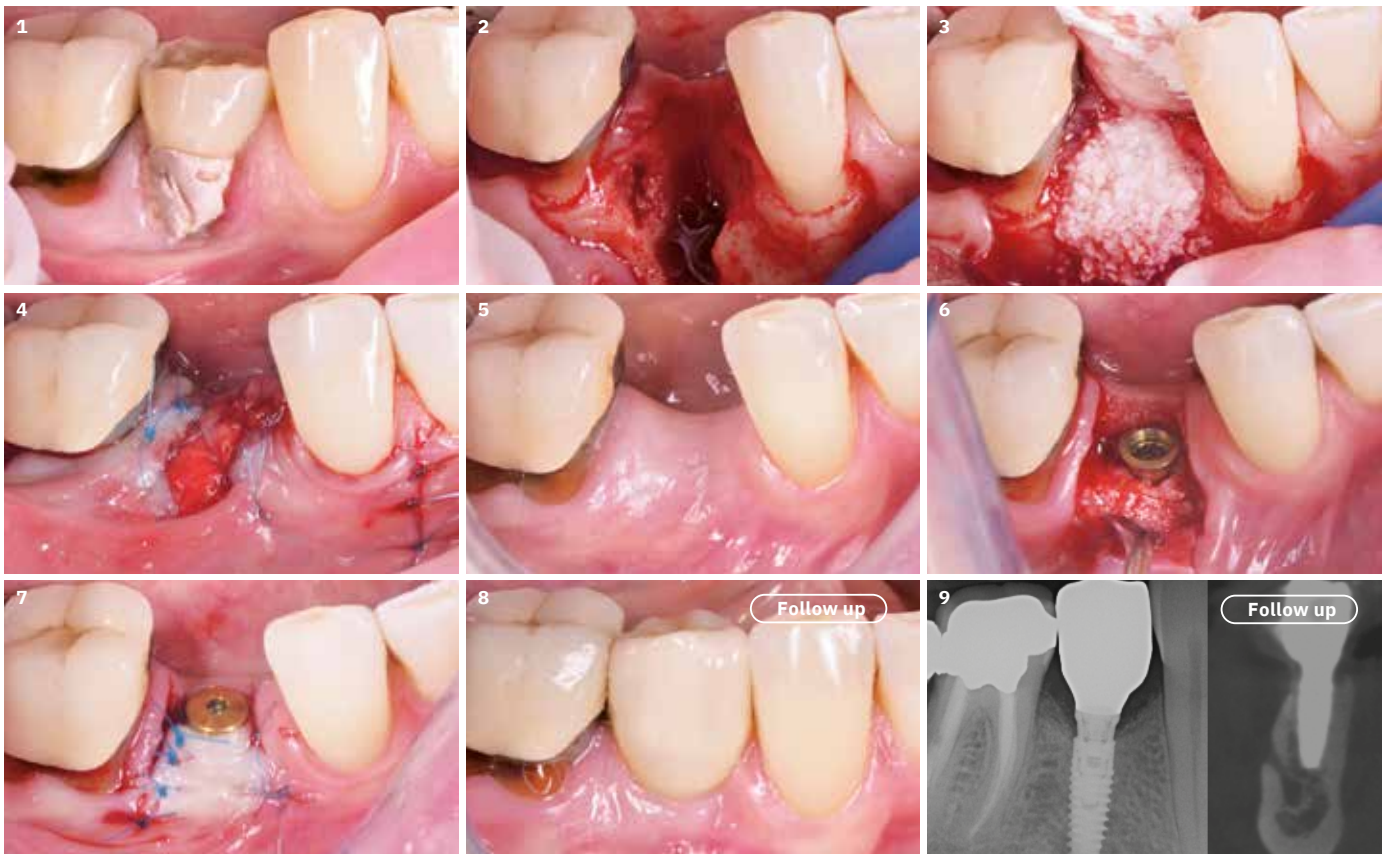Case description:

The patient (45 years old, female, non-smoker, no previous pathologies) is referred for extraction of tooth 45 and immediate implant placement. The site showed an increased probing depth and a marked bone loss.



Why did I use REGENFAST®?

After the extraction, I realized that the buccal wall was missing and I had to leave the membrane exposed. The regenerative potential of the site could be poor, so I decided to boost the biomaterials' effect with polynucleotides and hyaluronic acid.



Tooth extraction and immediate implant placement in the distal maxilla



Prof. Leonardo Trombelli
Ferrara, Italy



Why did I use REGENFAST®?

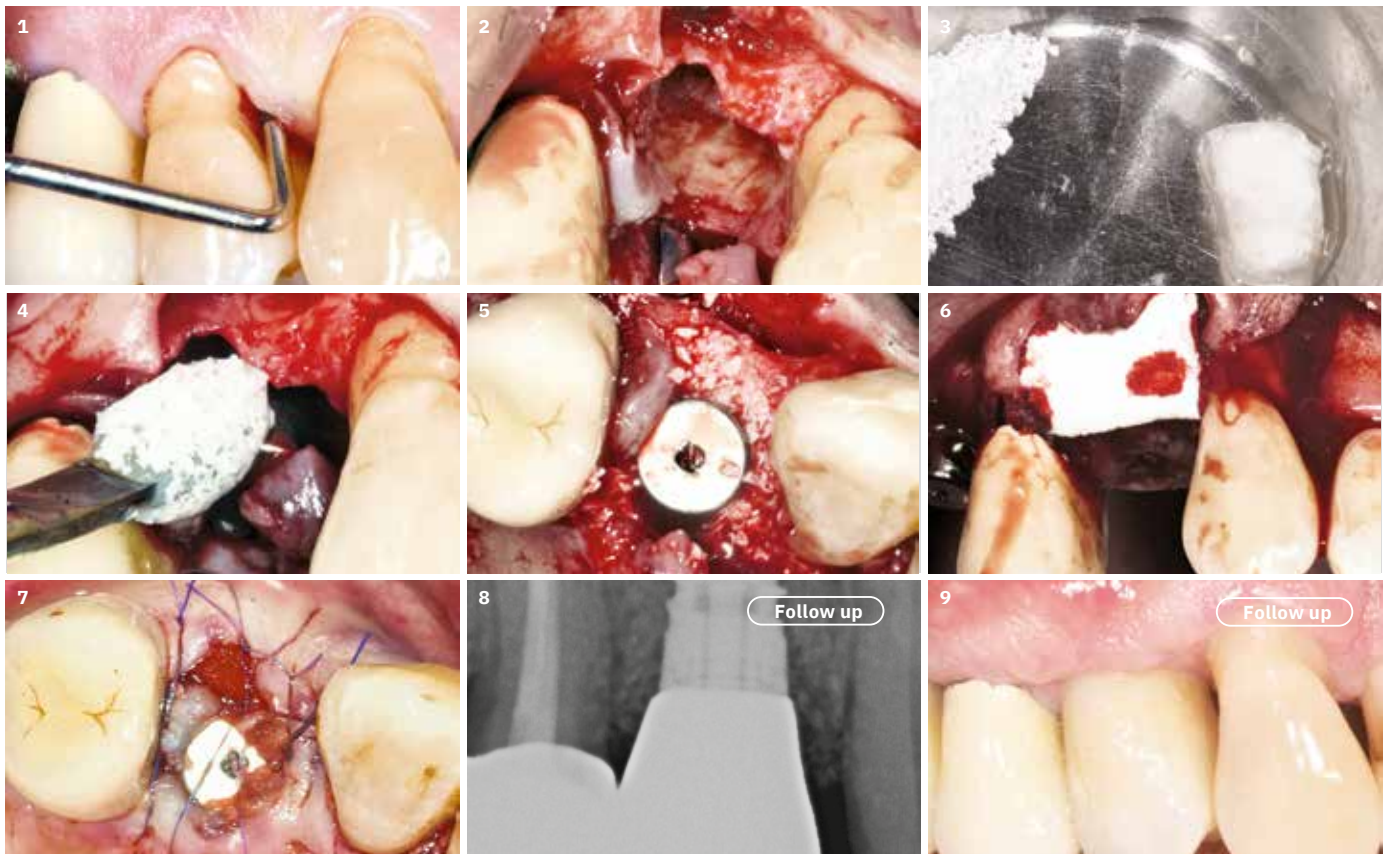
The combination of REGENFAST® with Geistlich Biomaterials was based on the assumption that the polynucleotide/hyaluronic acid gel is capable of enhancing both the hard and soft tissue healing process.

Case description:

The patient (57 years old female, non-smoker) showed 11 to 15 mm probing depth around tooth 14. After extraction, immediate implant placement was combined with Geistlich Bio-Oss® and Geistlich Fibro-Gide® soaked in REGENFAST®.

Case captions:

1 Tooth 14 with a 15 mm mesio-vestibular and 11 mm mesio-palatinal probing depth | **2** Post-extraction alveolus (vestibular view). | **3** Geistlich Bio-Oss® and Geistlich Fibro-Gide® combined with REGENFAST® | **4** Grafting material is used to fill the gap. | **5** Defect filled with grafting material. | **6** Positioning of Geistlich Fibro-Gide®. | **7** Suture of the surgical site with resorbable suture 6-0. | **8** Follow-up after 9 months: intraoral radiography | **9** Follow-up after 9 months: frontal view. Finalization of implant-prosthetic rehabilitation with placement of a single screwed prosthesis.



Multiple extractions and Ridge Preservation in the left maxilla



Dr. Marco Zeltner
Zurich, Switzerland

Case captions:

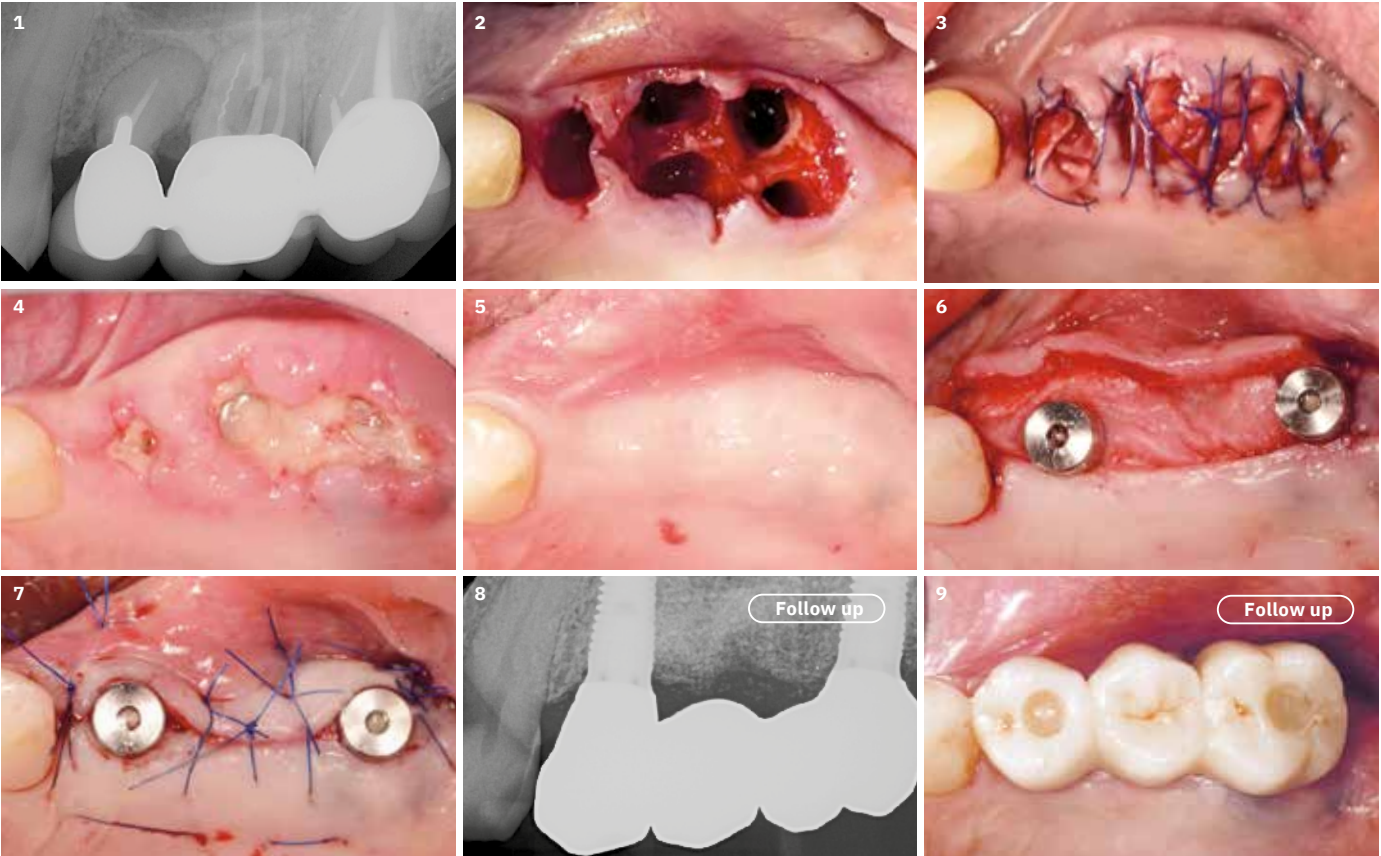
1 Radiographic situation at baseline | 2 Clinical situation after extraction of teeth 24, 26 and 27 | 3 Clinical situation after Alveolar Ridge Preservation with Geistlich Bio-Oss® and Geistlich Bio-Gide® | 4 Clinical situation after removal of the sutures 1 week after surgery | 5 Clinical situation 6 months after Ridge Preservation | 6 Clinical situation after flap elevation, guided implant placement and contour augmentation | 7 Clinical situation at the time of wound closure | 8 Radiographic situation after 1 year prosthetic rehabilitation | 9 Clinical situation after 1 year.

Case description:

The patient (41 years old, female, non-smoker) had several unrestorable teeth in the left maxilla. Due to her personal situation, it was decided to perform a late implant placement and to preserve the bone at the time of extraction using Alveolar Ridge Preservation. 6 months later, implant placement and subsequent prosthetic rehabilitation were performed.

Why did I use REGENFAST®?

For Ridge Preservation, Geistlich Bio-Oss® was filled into the socket, covered with a Geistlich Bio-Gide® membrane and left for secondary intention healing. REGENFAST® was used to accelerate wound healing in this open-healing situation in order to improve the situation for later implant placement.



Implant placement and contour augmentation in the maxilla



Dr. Elliott Ballantyne
Bath, United Kingdom



Why did I use REGENFAST®?

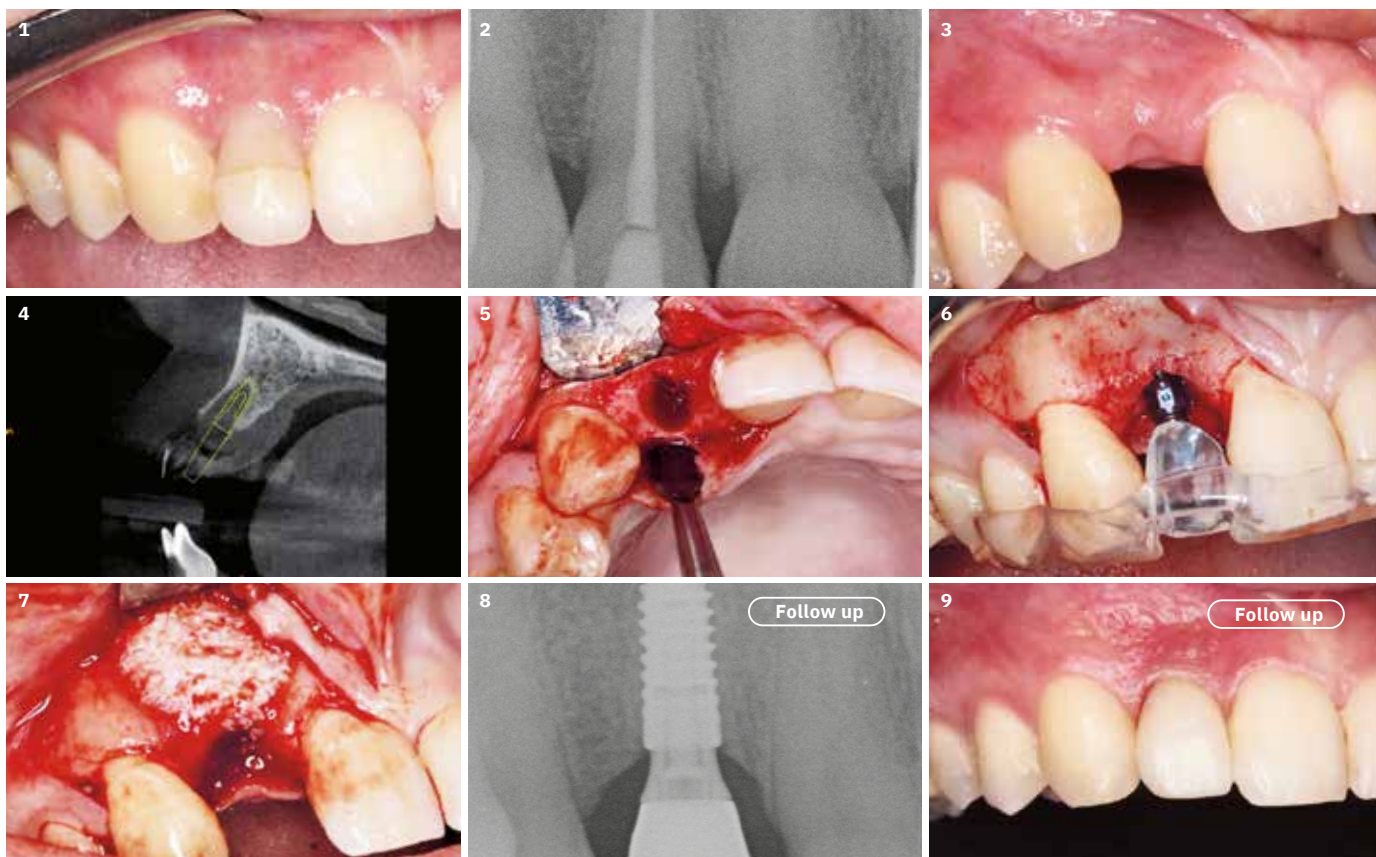
REGENFAST® was used for its unique viscoelastic properties to assist with graft stability helping to create a protective microenvironment promoting cell development and a faster, more efficient natural regenerative process. REGENFAST® has the ability to achieve this through the combination of its components – polynucleotides and hyaluronic acid.

Case description:

The patient (36-year-old female, non-smoker) presented with an unrestorable 12. This tooth had fractured at the coronal third buccally and extended subgingivally on the palatal aspect. The decision was taken to extract 12 with the provision of an immediate temporary denture followed by early implant placement after 8 weeks of healing.

Case captions:

1 Baseline situation. Unrestorable tooth 12. | **2** Pre-extraction radiograph with visible subgingival fracture line. | **3** 8 weeks post-extraction wound healing. | **4** The CBCT shows very thin buccal plate (< 1 mm) and thin palatal cervical margin of bone. | **5** Occlusal view of extraction socket thin buccal and palatal bony walls. | **6** Restoratively driven implant placement 3 mm below CEJ of adjacent teeth using surgical guide. | **7** Mixture of autogenous bone and Geistlich Bio-Oss® plus REGENFAST® applied to multiperforated cortical plate. The graft was then covered with a double layer of Geistlich Bio-Gide® membrane. A subepithelial connective tissue graft was harvested from the palate. The periosteum was released to ensure primary wound closure. | **8** Post-restoration radiograph showing healthy, stable periimplant bone levels. | **9** Post-restoration photograph with permanent crown on the day of fitting.



Treatment of a horizontal bone defect and soft-tissue deficit in the distal mandible



Dr. Mario Beretta
Milano, Italy

Case captions:

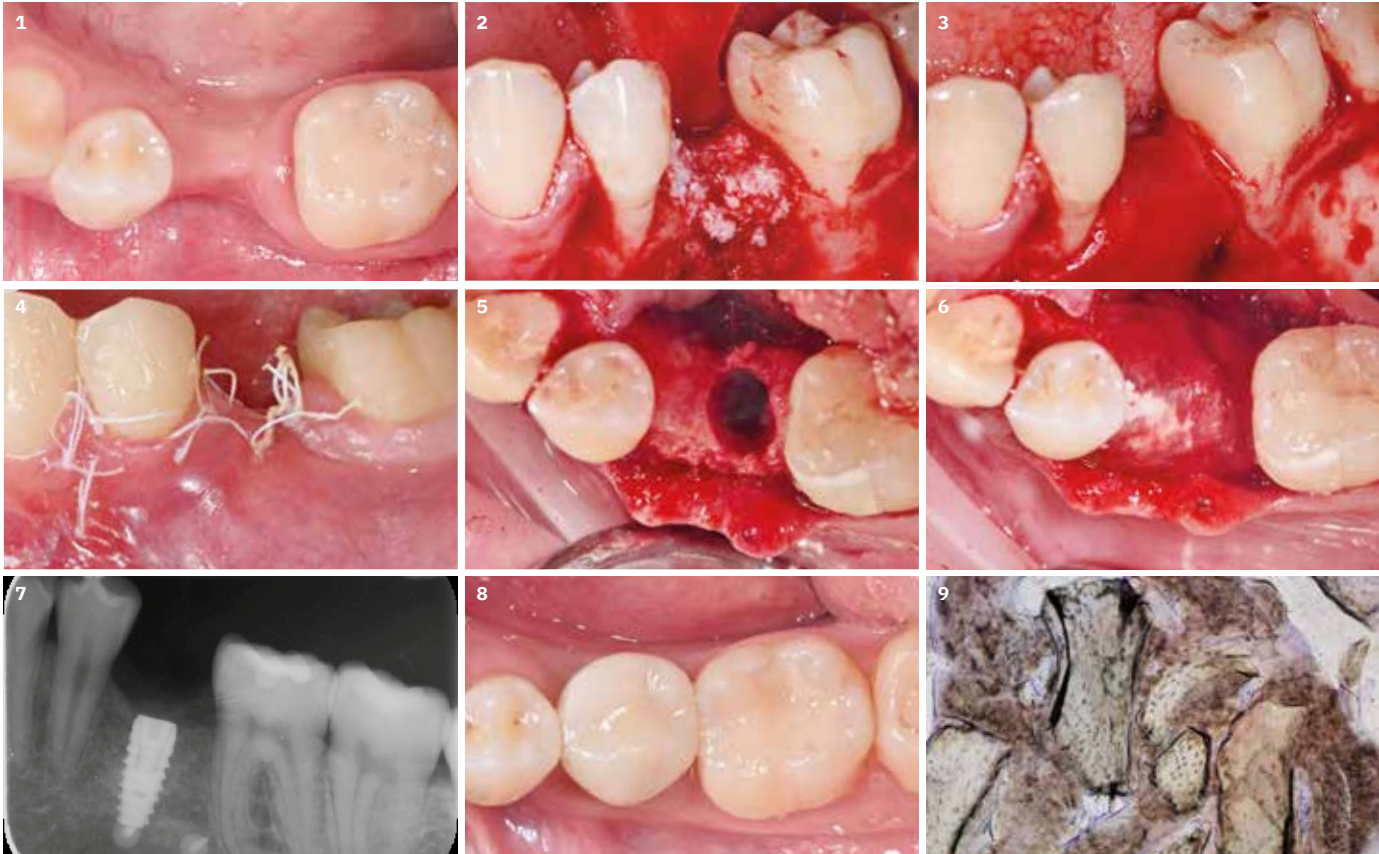
1 The presence of severe horizontal atrophy in the edentulous site is clinically visible. | **2** After flap elevation, Geistlich Bio-Oss® is mixed with REGENFAST® and positioned at the level of the defect for the reconstruction of the alveolar crest. | **3** A Geistlich Bio-Gide® Compressed membrane is fixated with surgical pins first on the lingual side and then on the vestibular side. | **4** Soft tissues healing after 7 days. | **5** Reopening after 5 months and taking a trephine biopsy for histology. | **6** An implant (3.8 × 9 mm) is placed and the site is augmented again with Geistlich Bio-Oss® mixed with REGENFAST® and stabilized with Geistlich Bio-Gide® Compressed. | **7** Radiographic image after 3 months at the time of reopening. | **8** Healing with the provisional. | **9** Histological ground section of the regenerated site. For more details on histological features after GBR with REGENFAST® see page 10.

Case description:

The patient (24 years old, female, no previous pathologies) presented with severe horizontal atrophy at an edentulous saddle in site 35. The situation was not compatible with the planned insertion of an implant of correct diameter and length.

Why did I use REGENFAST®?

In this GBR surgery, I used REGENFAST® to speed up the healing process and to reduce the treatment time. After 5 months, the newly formed bone was really hard and mature from a clinical point of view. Post-op discomfort proved to be less than with the standard procedure.



Early implant placement with Guided Bone Regeneration in the distal mandible



Dr. Emmanuelle Ettegui
Paris, France



Why did I use REGENFAST®?

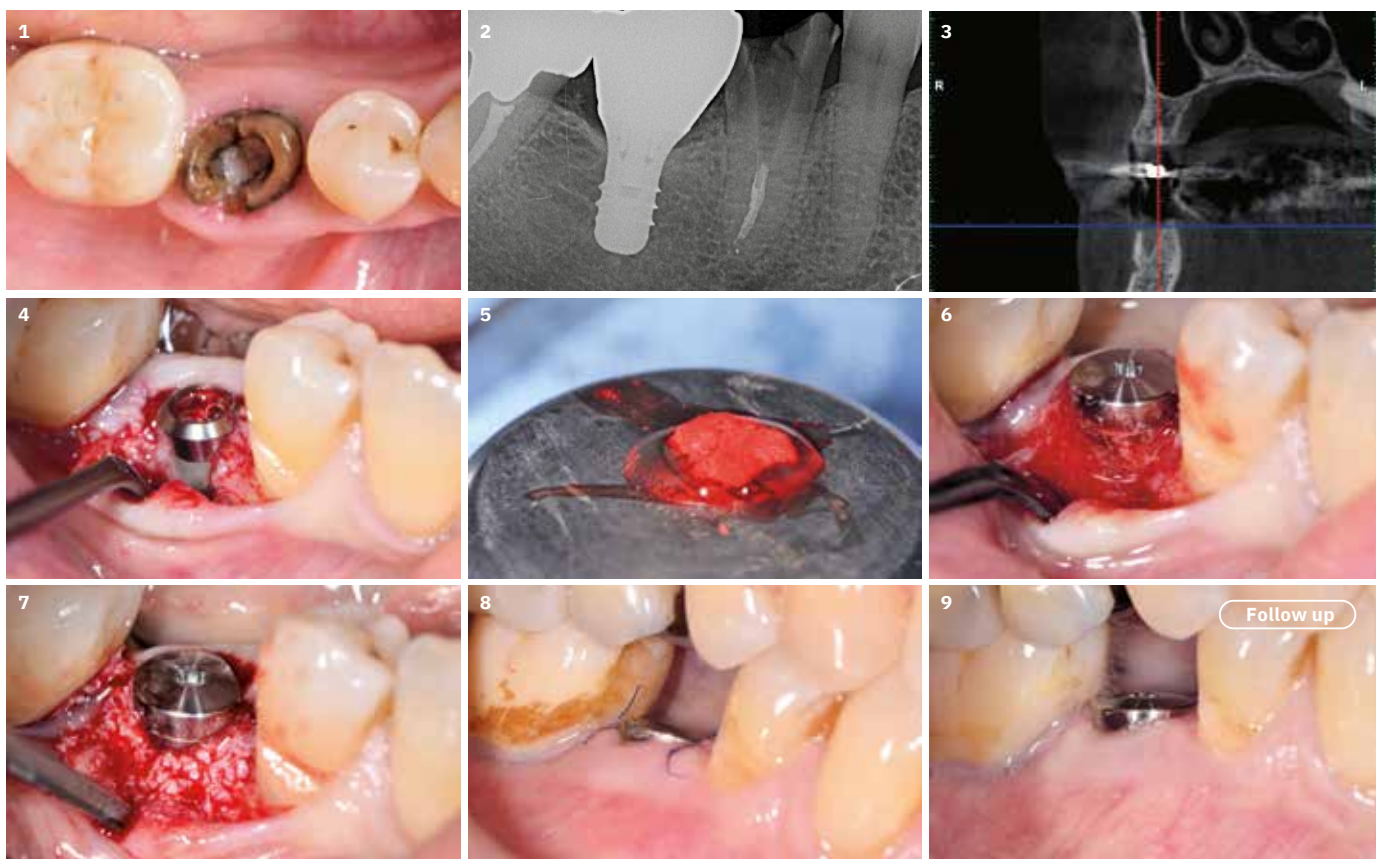
I applied REGENFAST® during an early implant placement associated with Guided Bone Regeneration, autogenous bone and xenograft, to promote cell trophism and tissue hydration. I didn't like the consistency of the mixture with the autogenous bone, but the healing was good and the operating procedures were simple.

Case description:

The 71-year-old, healthy patient came to the office to have the fractured tooth 45 extracted and replaced with an implant. Guided Bone Regeneration was carried out combining autogenous bone from drilling and Geistlich Bio-Oss®, both mixed separately with REGENFAST®.

Case captions:

1 Occlusal view of the initial situation. | **2** Radiographic image: no infection noticed around the tooth apex. | **3** Preoperative two-dimensional (2D) X-ray image from the CBCT. | **4** Implant placed in site 45 and superficial bone defect. | **5** Autologous bone harvested during implant site preparation and mixed with REGENFAST® | **6** Application of a mixture of autogenous bone and REGENFAST® on the exposed implant surface. The autogenous bone has lost its consistency and is more difficult to apply. **7** Application of Geistlich Bio-Oss® mixed with REGENFAST®. | **8** Healing at 14 days, removal of suture material (horizontal mattress sutures using monofilament material, Séralène 6.0). | **9** Healing at 45 days, validation of osseointegration.



Vertical and horizontal bone augmentation in the distal maxilla



Dr. Alfonso Rao
Bristol, United Kingdom

Case captions:

- | 1 Yxoss CBR® mesh in place showing good margin adaptation.
- | 2 Locally harvested autogenous bone taken from the defect site using a safescraper.
- | 3 Mixing the autogenous bone with Geistlich Bio-Oss®, small granules in a 50/50 ratio.
- | 4 Preloading of the Yxoss titanium mesh with the grafting material.
- | 5 Addition of REGENFAST® to the grafting material within the mesh in order to enhance the consistency of the graft.
- | 6 Further addition of REGENFAST®, 0.4 ml is mixed with approx. 1 g of autogenous bone and Geistlich Bio-Oss®.
- | 7 The Yxoss CBR® mesh is fixated using 2 buccal and 1 palatal tacks for stability.
- | 8 At the 9-months follow up, very nice healing is visible and good bone volume is achieved.

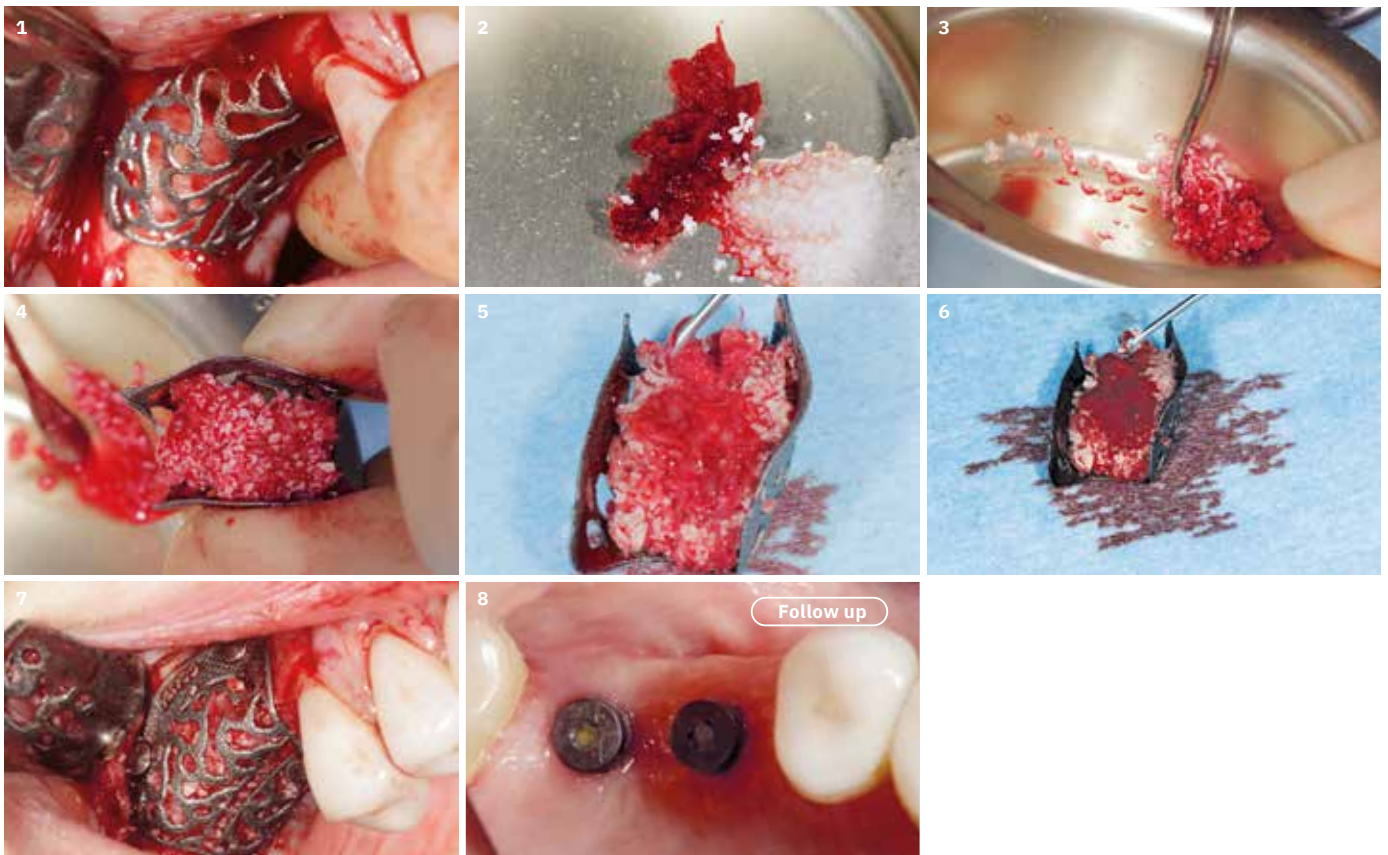
Case description:

The patient (mid-40's, female, medically fit and well) was referred for horizontal and vertical augmentation due to bone loss following extraction of a molar and pre-molar several years previously.



Why did I use REGENFAST®?

In my clinical experience I have noticed that the use of REGENFAST® enhances the healing of soft and hard tissue. It also reduces the healing time and as a consequence improves the patient satisfaction in this case.



Treatment of a horizontal bone defect and soft-tissue deficit in the distal mandible



Dr. Jacques Hassid
Colmar, France



Why did I use REGENFAST®?

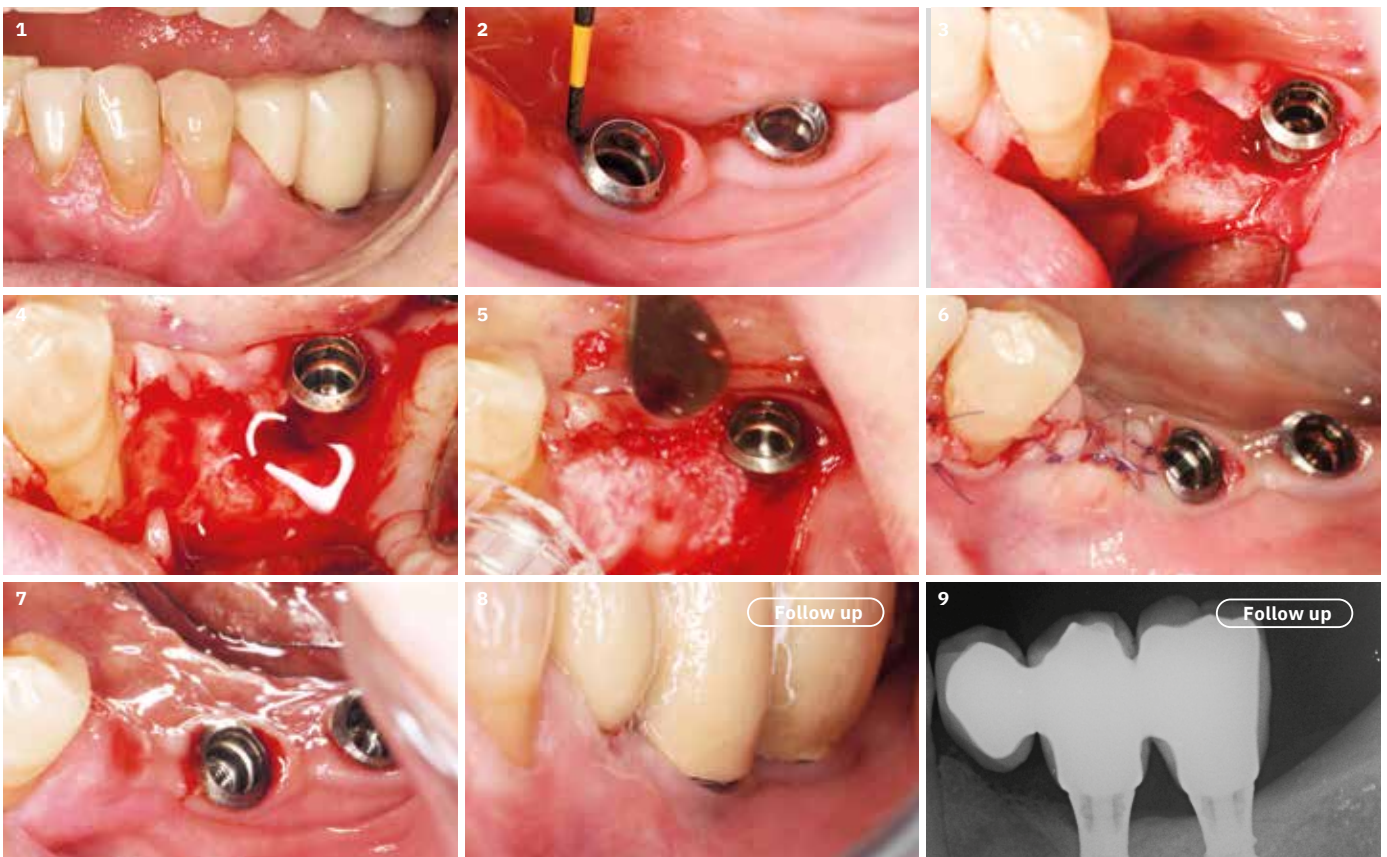
I've used REGENFAST® several times for different treatments (gingival graft, peri-implantitis, Guided Bone Regeneration). In summary, my feelings after 1 year are: simplicity of use, speed-up of wound healing, no adverse reaction, easier handling and mixing with Geistlich Bio-Oss®.

Case description:

The patient (65 years old, female) was referred to our clinic with discomfort during masticatory function. The clinical and radiographic examination revealed an aggressive circumferential peri-implantitis lesion around an implant placed 3 years previously and a bone cyst beside the teeth.

Case captions:

1 Pre-operative situation: Implants on 36 and 37 | **2** Probing pocket depth (PPD) = 6 mm on implant 46 | **3** Crestal and vertical incision and flap elevation. Defects are visible, cleaning with the AIR-Flow® and decontamination with 0.2% CHX | **4** Application of REGENFAST® before the addition of Geistlich Bio-Oss®. | **5** Filling of the defects with Geistlich Bio-Oss® mixed with REGENFAST®. | **6** Tension-free flap repositioning using sutures (6-0 slower resorption) | **7** Post-op view after 15 days. Sutures removal. Healing uneventful. | **8** At 1-year follow-up no signs of bleeding on probing, thin gingiva noticed and good oral hygiene. | **9** Radiographic control at 1 year shows a stable bony situation.



Regenerative treatment of a peri-implant defect

Dr. David Palombo
Milano, Italy



Case captions:

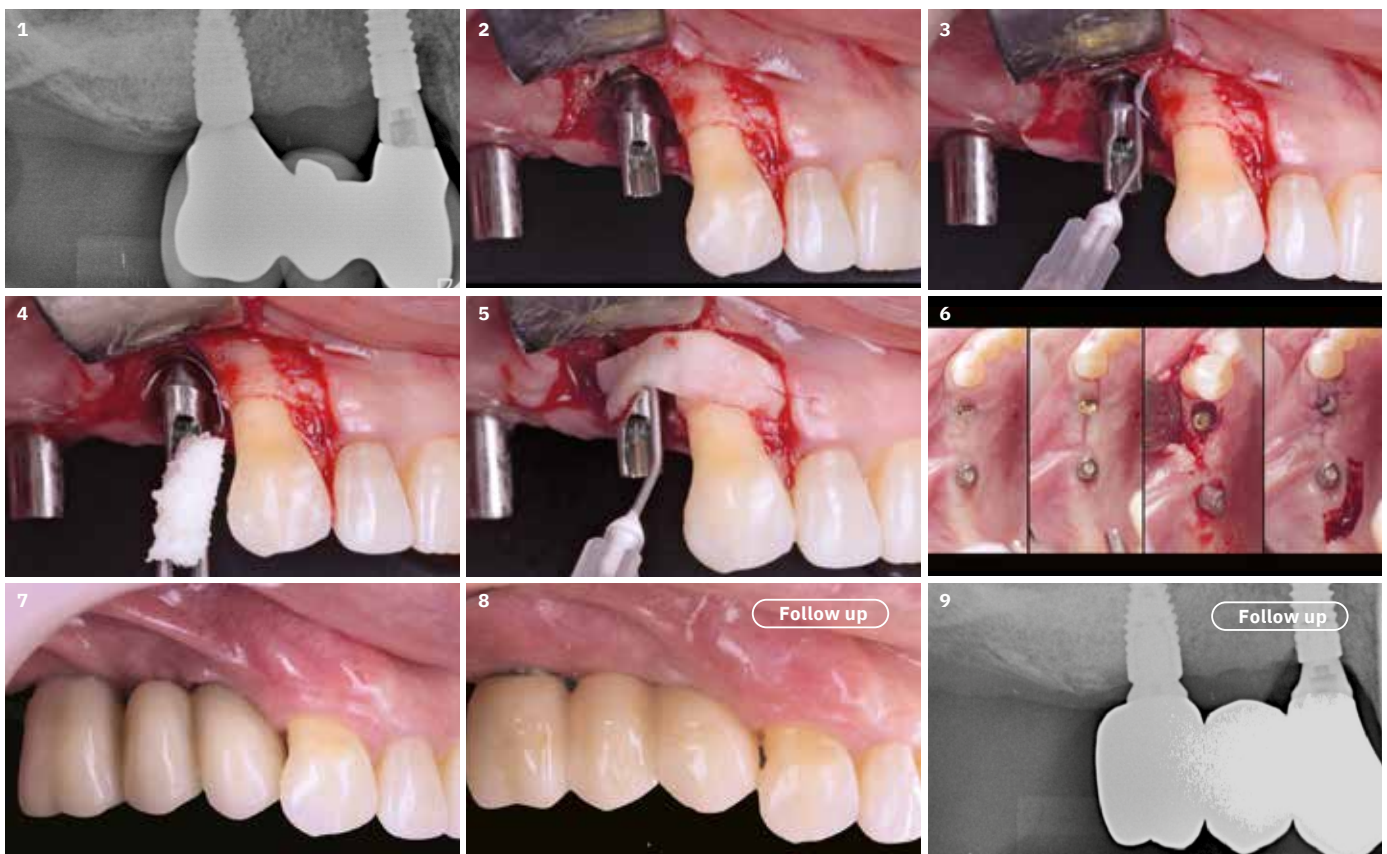
1 Radiographic image of the initial situation: Implant at site 14 shows peri-implant bone loss | **2** After flap opening, the defect is visible | **3** After thorough cleaning, REGENFAST® is applied into the defect | **4** Geistlich Bio-Oss® Collagen soaked with REGENFAST® is applied | **5** A free gingival graft harvested from the palate is applied on tooth 13 and the affected site | **6** Healing progress from wound closure until 1 month | **7** Temporary crowns on multi-unit abutments. | **8** Permanent crowns on multi-unit abutments 1 year after surgery | **9** The radiographic image 1 year after surgery shows the good bony situation.

Case description:

A patient (68-year-old female, non-/smoker) presented with a peri-implant bone defect at site 14. After cleaning, regenerative surgery was performed in conjunction with Geistlich Bio-Oss® Collagen soaked in REGENFAST®.

Why did I use REGENFAST®?

In challenging clinical scenarios, the opportunity to benefit from an adjunct, easy-use biological booster, may be an innovative strategy to improve results and increase the predictability of our treatments.



Regenerative treatment of a site after osteonecrosis of the jaw



Dr. Alberto Pispero
Milano, Italy



Why did I use REGENFAST®?

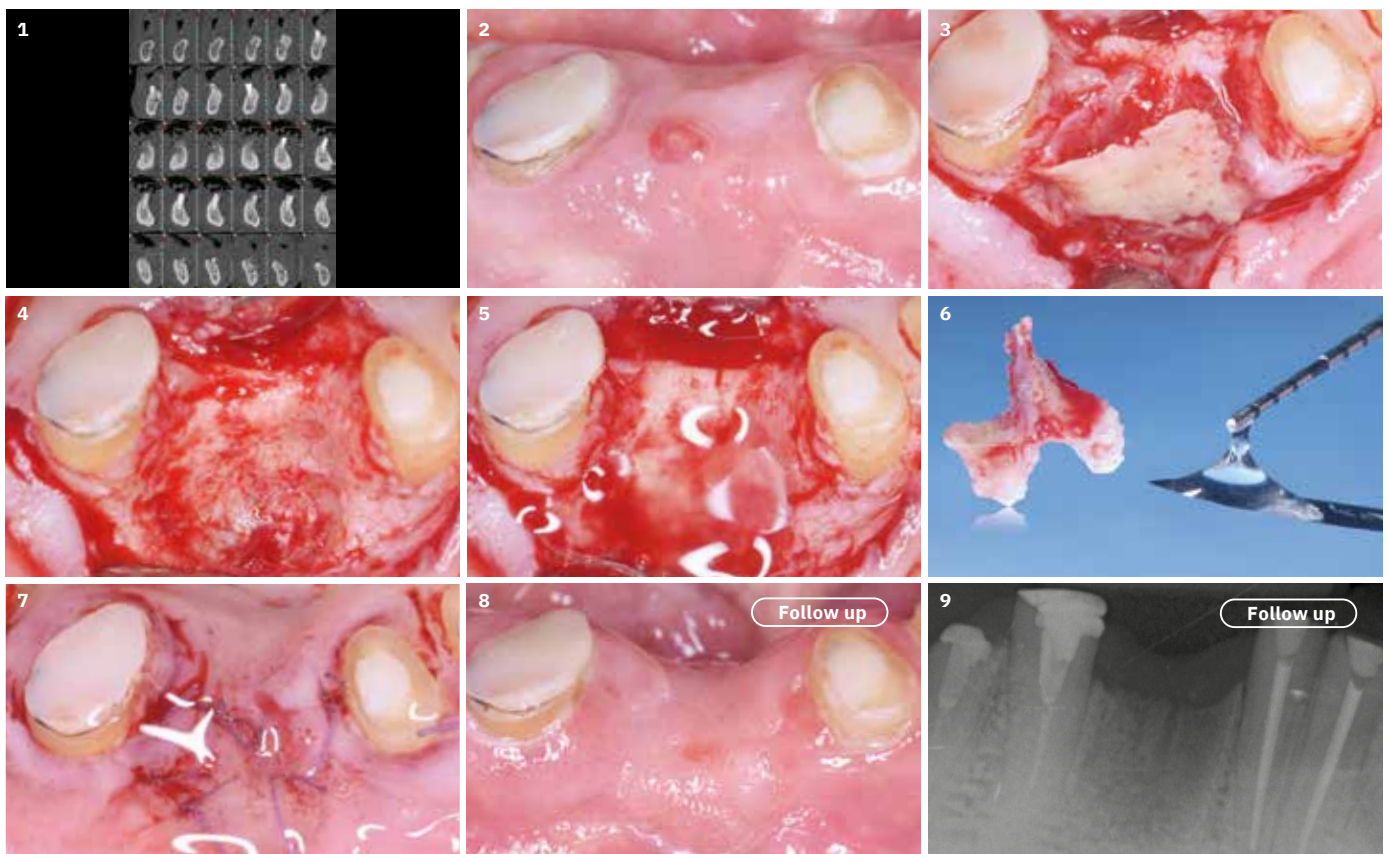
I used REGENFAST® to stimulate the healing of the surgical site. The action of polynucleotides associated with hyaluronic acid seems to speed up soft-tissue healing. This aspect is essential to increase the chances of bone healing in patients at risk of medication-related osteonecrosis of the jaw.

Case description:

Following the extraction of tooth 42, a drug-induced osteonecrosis was diagnosed and treated. One week after the treatment, the clinical picture had improved and the symptoms were significantly reduced.

Case captions:

1-2 Fistula in relation to the edentulous crest through which the bone crest can be probed. Cone beam sections show a fragment of necrotic bone. | **3** Intraoperative image of the necrotic bone fragment, corresponding to the vestibular cortex of the element previously extracted. | **4** The removal of the fragment is simple because of complete sequestration. | **5** The clinically healthy bone tissue is curetted and a generous layer of REGENFAST® is applied before wound closure by primary intention. | **6** The viscosity of the product allows it to remain in the intervention site. Contact with saliva would cause rapid dispersion in the oral cavity. | **7** After the suture, the excess part of the product is applied on the suture line. | **8** Perfectly healthy tissues with no signs of pathology three months after the surgery. | **9** The intraoral radiographic image confirms the bone healing of the treated site.



Product range

Geistlich Bio-Oss®



Small granules

Available sizes:

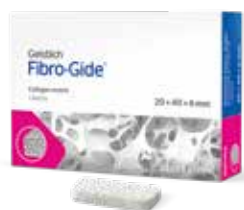0.25 g, 0.5 g
1.0 g, 2.0 g
(1.0 g ≈ 2.0 cm³)

Large granules

Available sizes:

0.5 g, 1.0 g
2.0 g
(1.0 g ≈ 3.13 cm³)

Geistlich Fibro-Gide®



6 mm thickness

Available sizes:

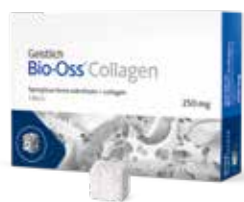15 × 20 mm
20 × 40 mm

3 mm thickness

Available sizes:

15 × 20 mm
20 × 40 mm

Geistlich Bio-Oss® Collagen



Geistlich Bio-Oss®

(small granules) +
10% collagen (porcine)

Available sizes:

50 mg
100 mg
250 mg
500 mg

Geistlich Bio-Gide®



Geistlich Bio-Gide®

Available sizes:

13 × 25 mm
25 × 25 mm
30 × 40 mm

Geistlich Bio-Gide® Shape

Available size:

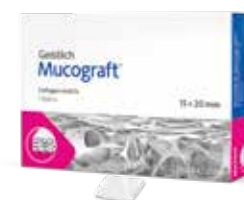14 × 24 mm

Geistlich Bio-Gide® Compressed

Available sizes:

13 × 25 mm
20 × 30 mm

Geistlich Mucograft®



Geistlich Mucograft®

Available sizes:

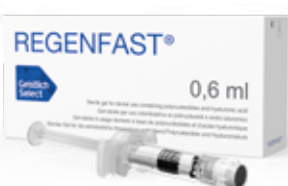15 × 20 mm
20 × 30 mm
30 × 40 mm

Geistlich Mucograft® Seal

Available sizes:

8 mm
12 mm diameter

REGENFAST®



Available sizes:

0.3 ml, 0.6 ml, 0.8 ml

Make an impact with REGENFAST®

Start your journey now.

Based on clinical experience, treatment with REGENFAST® promotes faster and physiological repair: 98 percent of users gave the early healing a score of ≥ 7 on a 1–10 scale (1=poor, 10=excellent).²

Now it is time to accelerate your regenerative treatment solutions!

Buy

Can't wait to improve your patients' experience?



VISIT OUR
E-SHOP NOW!

Try

Want to find out more about REGENFAST® before purchasing?



BOOK A PRODUCT
DEMO WITH OUR
PRODUCT SPECIALISTS!

Discover

Want to stay up-to-date with news around Geistlich, Geistlich Select products and innovative solutions for your practice?



VISIT OUR GEISTLICH BLOG
"THE REGENERATION EXPERT
HUB!"



More details about our
distribution partners:
www.geistlich-pharma.com

Headquarters

Geistlich Pharma AG
Bahnhofstrasse 40
6110 Wolhusen, Switzerland
Tel. +41 41 492 55 55
Fax +41 41 492 56 39