

Yxoss CBR[®]

Customized Bone Regeneration



Customized Solutions



marketed by

Geistlich

the regeneration
experts

Yxoss CBR[®] – The future is now

The first customized 3-D printed bone regeneration solution for complex bone defects

3-D


Innovative solution for regenerating **complex alveolar bone defects** by taking advantage of CBCT data combined with **3-D printing technology**




Opportunity to **reduce surgery time** without complex adaptations



High **stability** and space maintenance





Optional: Unique **integrated implant positioning** in the surgical planning – **Yxoss CBR® backward**



Easy Removal Design® with pre-defined breaking points for easy removal of Yxoss CBR® on re-entry



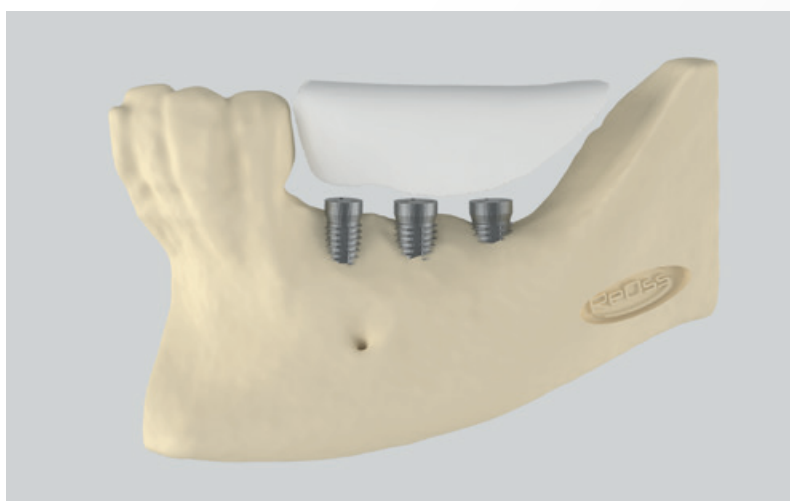

ReOss® calculates the necessary **augmentation volume** for your case planning

Contents

2–3	Yxoss CBR® – The future is now
4	ReOss® – Quality and precision are our strengths
5	Soft tissue management is the key to success
6–7	Surgical procedure step-by-step
8–15	Clinical cases with Yxoss CBR® classic
16–17	“This technique reduced the difficulties to less than half” – Interview with Prof. Matteo Chiapasco
18–19	Yxoss CBR® protect – Designed for an even easier removal
20–21	Clinical cases with Yxoss CBR® protect
22	Yxoss CBR® backward
23	MyReOss ordering process

ReOss® – Quality and precision are our strengths

We make a difference by providing a specified product range based on individual solutions for your patients.

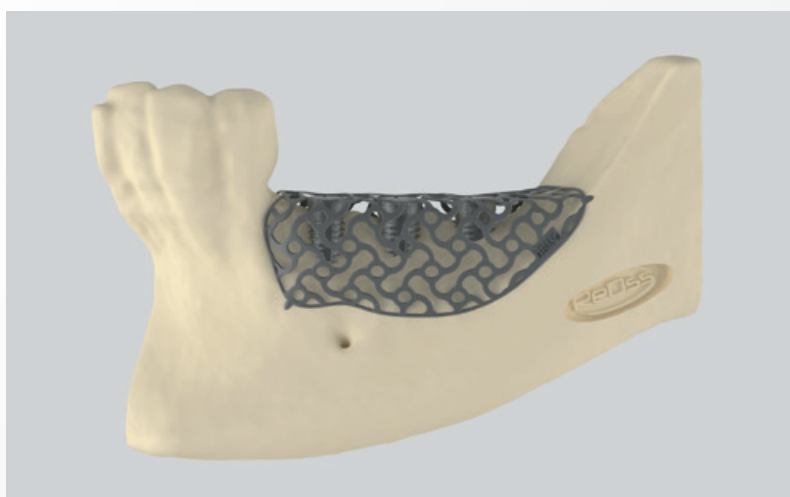


ReOss® uses the most up-to-date CAD/CAM technology available to satisfy patient-specific requirements regarding a planned bone augmentation. In a patented process, a contoured, form-stable scaffold is 3-D printed out of the purest titanium based on CT or CBCT images, allowing for customized bone regeneration (CBR®).

Yxoss CBR® has revolutionized oral bone augmentation by customizing the commonly used “titanium mesh”, using a digital workflow to fit the individual anatomy of each patient.



Each titanium scaffold is custom-made for a precision fit that accurately reflects the specific patient data provided. Time-consuming impressions, cutting, shaping and adapting are no longer necessary and sharp edges from cutting conventional meshes are entirely eliminated.



Online 3-D Design Viewer

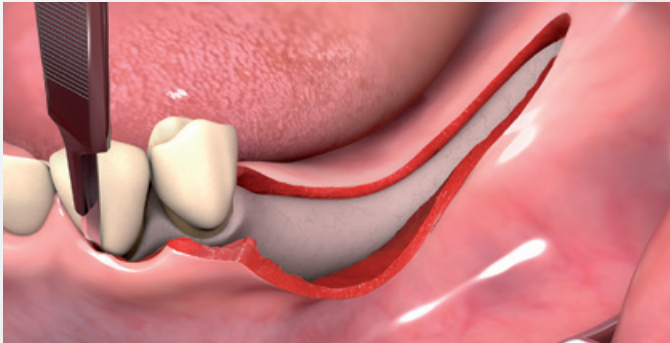
You can easily review the customized scaffold design online via your PC, tablet, or smart phone. The high-resolution 3-D image can be rotated in any direction, zoomed for details as well as commented for change requests. No need to install an app.



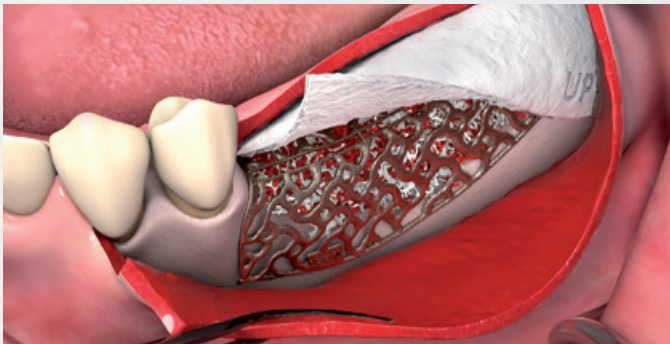
Soft tissue management is a key to success

Options for the flap design

Ridge incision technique¹

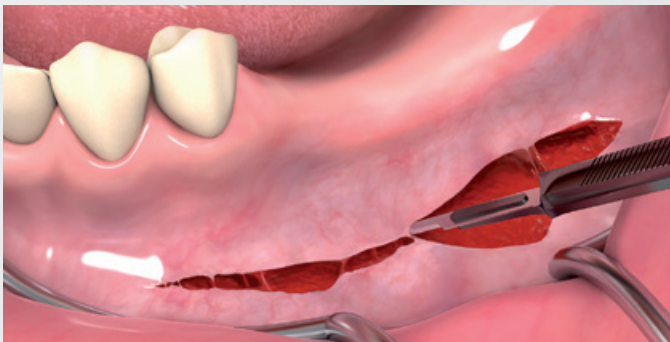


- › Crestal incision of the mucosa and the periosteum
- › No releasing incision – extension 3-4 teeth to the posterior (if possible)
- › Flap design: Full thickness flap

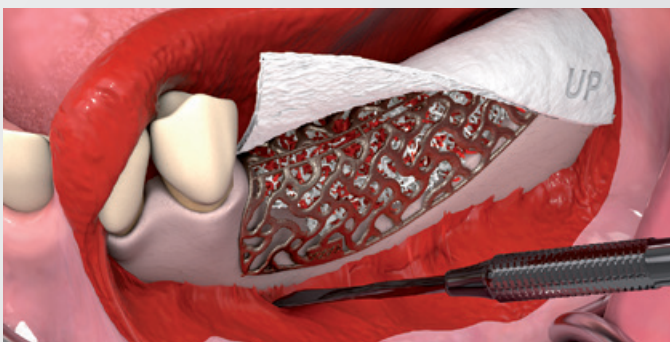


Once Yxoss CBR® is placed and the augmentation is performed according to the principles of guided bone regeneration, the flap can be mobilized by a periosteal releasing incision deep in the vestibular area. This will allow tension-free flap closure.

Poncho-technique¹



- › High vestibular incision of the mucosa, muscle and periosteum
- › Preparation and mobilization of the flap
- › No releasing incision
- › Flap design: Full thickness flap

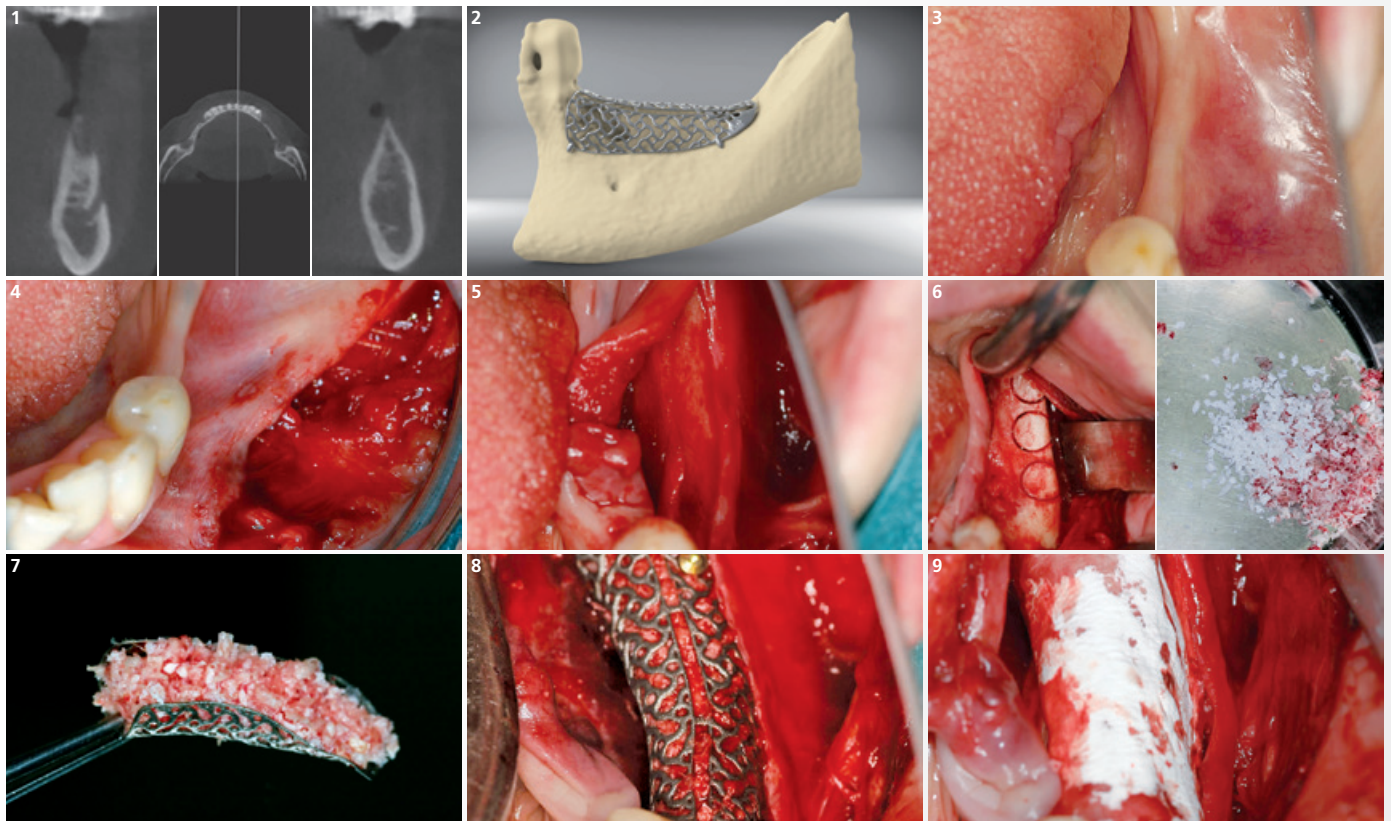


This poncho technique is preferred in pronounced vertical defects. After incision, preparation of a mucoperiosteal flap, debridement of scar tissue, and exposure of the defect is conducted. A passive tension-free fit of the Yxoss CBR® is then ensured.

¹ Sagheb K et al., Int J Implant Dent 2017; 3(1):36. (adapted by Dr. Marcus Seiler MSc MSc).

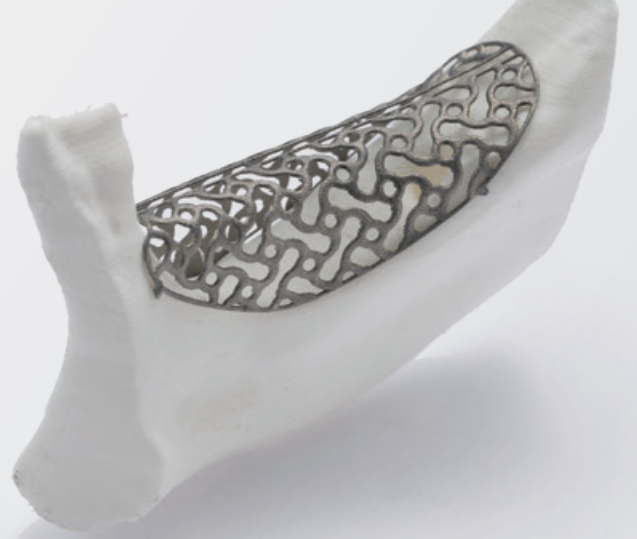Surgical procedure step-by-step

The planning of the patient's case takes local and general patient-specific risk factors into consideration according to the principles of backward planning for implant positioning. The horizontal and vertical bony defect can be regenerated with Yxoss CBR® via bone regeneration. The following case¹ highlights step-by-step the important procedures to regenerate the bone (horizontal and vertical) with the 3-D printing technology according to Dr. Marcus Seiler MSc MSc.



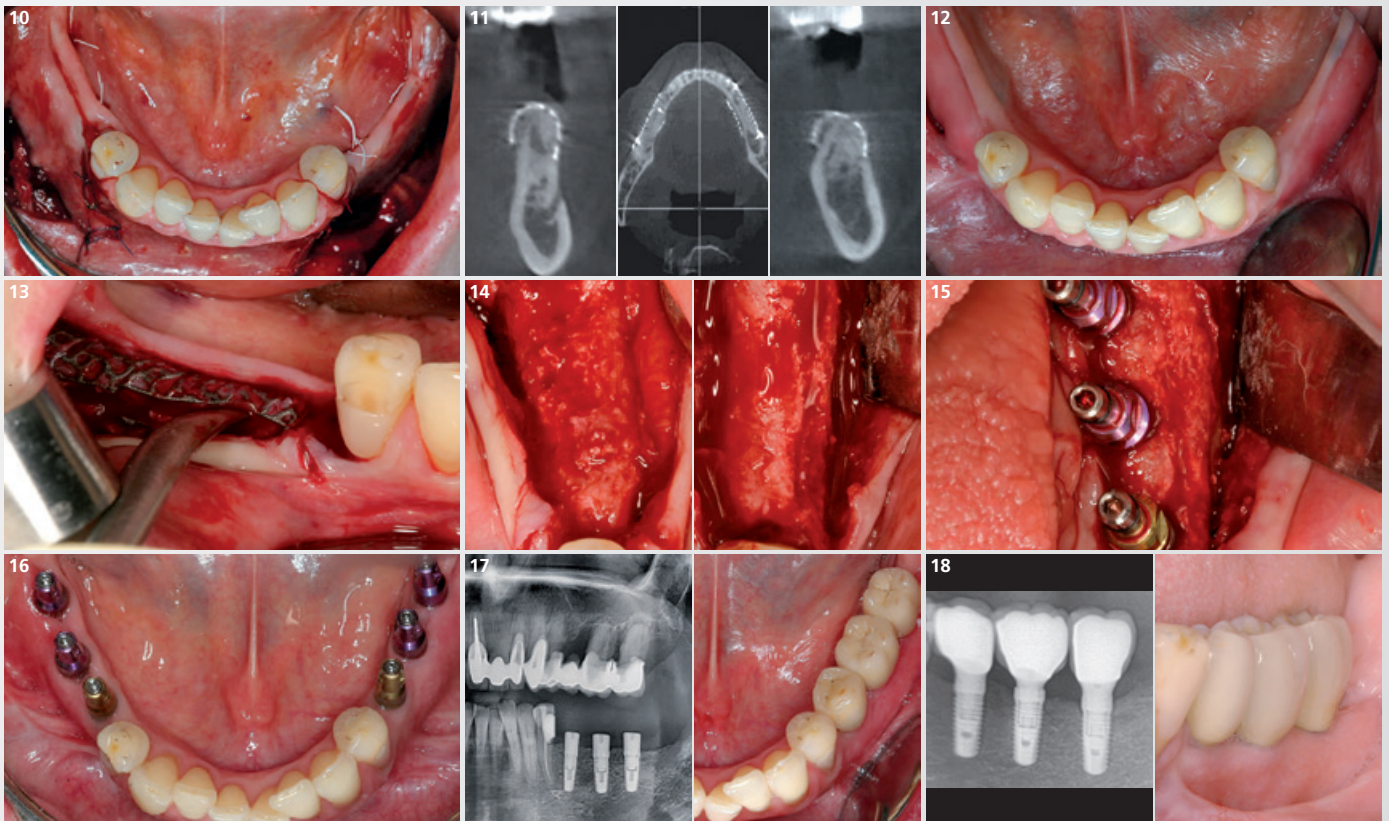
- 1 The basis for planning implant therapy is clinical and radiological diagnosis with a CBCT scan.
- 2 A precise 3-D planning model will be created based on CBCT data. Adaptations of the exact shape are possible, depending on the surgeon's preference and feedback.
- 3 The usual oral surgery and implantology hygiene provisions apply for the use of Yxoss CBR® intra-operatively. The same applies to patient medication.
- 4 The opening incision should be designed in accordance with the extent, location and with respect to the anatomical structures of the region to be augmented.
- 5 Subsequent steps are the preparation of a mucoperiosteal flap, debridement of scar tissue and the exposure of the defect. Sufficient blood supply of the flap is favored by a flap with a wide base.
- 6 Autologous bone can be harvested from the usual intraoral donor sites and can be mixed with bone substitutes (e.g. Geistlich Bio-Oss®).
- 7 The Yxoss CBR® is initially filled with autologous bone and bone substitute material (e.g. Geistlich Bio-Oss®).
- 8 Yxoss CBR® is fixed on the existing residual bone with an osteosynthesis screw. The titanium screw can generally be introduced, depending on the intended position, through any opening of the titanium grid. The edges of Yxoss CBR® rest on the underlying bone tissue.
- 9 A resorbable membrane (e.g. Geistlich Bio-Gide®) should be placed over the Yxoss CBR® to prevent ingrowth of soft-tissue and to support soft-tissue regeneration over the titanium frame.

¹ Surgery and concept by Dr. Marcus Seiler MSc MSc.



Find more information and videos here!

Scan the QR code with your device
to get to the website

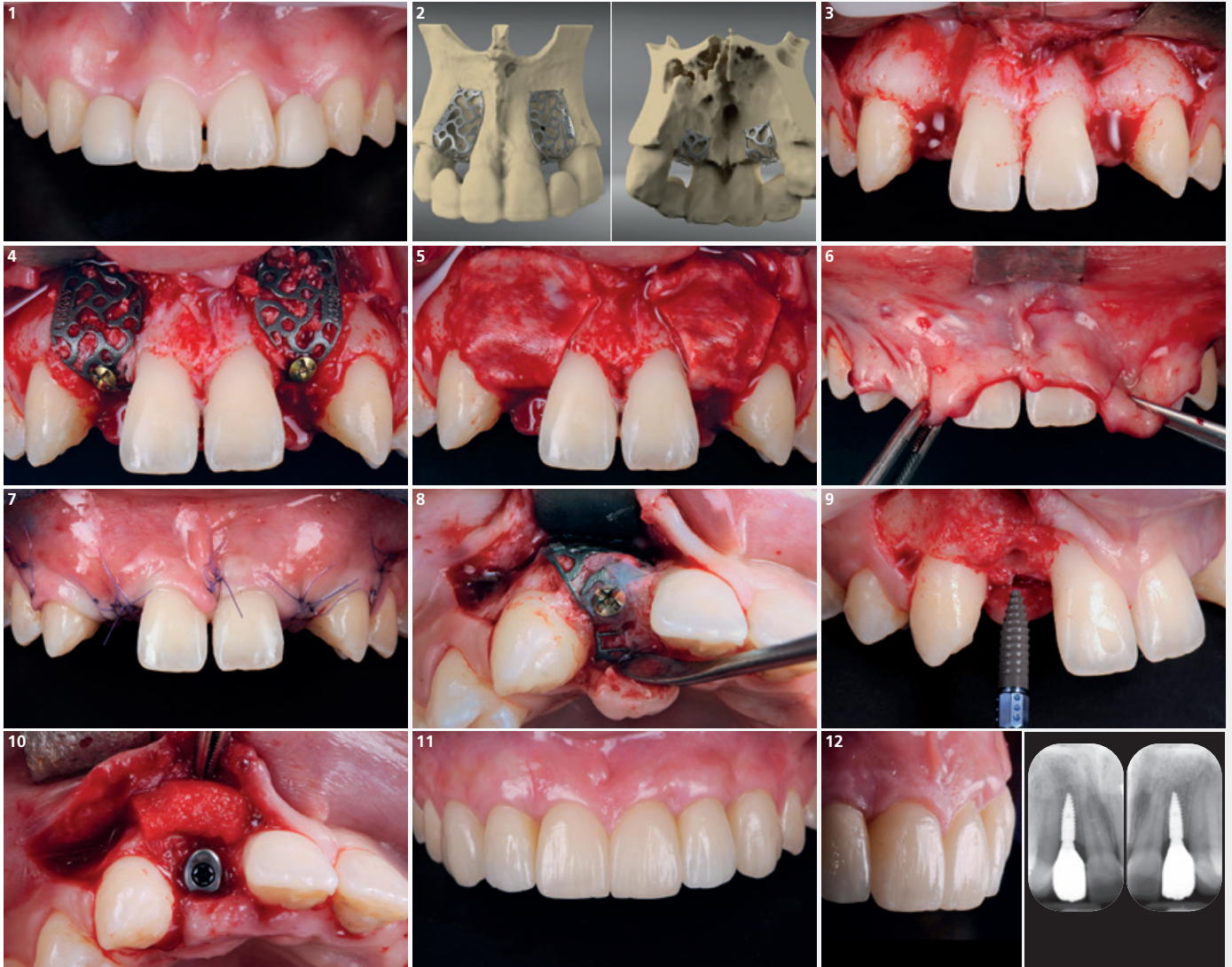


- 10** The wound should be closed completely whenever possible. The mucoperiosteal flap is positioned tightly but tension-free over Yxoss CBR® with single interrupted and deep mattress sutures. Pressure on the augmented crest has to be avoided. Dentures are not to be applied.
- 11** Before reopening, clinical and radiological diagnosis are to be taken into consideration.
- 12** Reopening of the augmented site approx. 4 to 6 months post surgery and depend on the defect geometry, at latest 9 months after initial surgery.
- 13** After removing the fixation screws, Yxoss CBR® can be easily removed using preset breaking points.
- 14** Newly formed vital bone is regenerated up to the contour defined by the shape of the Yxoss CBR®.
- 15** Insertion of implants into the augmented alveolar ridge according to the prosthetic position.
- 16** Prosthetic restoration is carried out in accordance with the usual precautions.
- 17** Follow-up and radiological evaluation should be performed according to the standardized recommendations of the respective dental societies.
- 18** Clinical and radiological imaging of longterm outcome in this case at 5-year follow-up.

1 Babich H et al. Cell Biol Toxicol. 1995; 11(2): 79-88.
2 Mariotti AJ, Rumpf DA. J Periodontol 1999; 70(12): 1442-1448.
3 Wilken R et al. SADJ. 2001; 56(10): 455-460.

Horizontal/Vertical Defect (Bilateral 1 tooth gap) – Anterior Maxilla

Surgery and concept by Dr. Paolo Casentini (Milan, Italy)



1 Initial clinical situation with adhesive Maryland prostheses and vertical / horizontal bone defect.

2 Digital 3-D planning of customized bone regeneration with Yxoss CBR®.

3 Exposure of bone defects after lifting a full thickness flap.

4 Application of the 2 Yxoss CBR® and fixation with osteosynthesis screws. The defects were treated with autologous particulate bone grafting mixed with Geistlich Bio-Oss® in a 50% ratio.

5 Positioning of two Geistlich Bio-Gide® on top of Yxoss CBR® to optimize the barrier effect.

6 Flap mobilization is a fundamental element in any technique of bone volume augmentation.

7 Flap closure with absorbable sutures 6-0.

8 7 months post-surgery, a favorable bone augmentation could be achieved...

9 ...followed by implant a prosthetically guided implant placement (Straumann® BLT 2.9 x 10 mm).

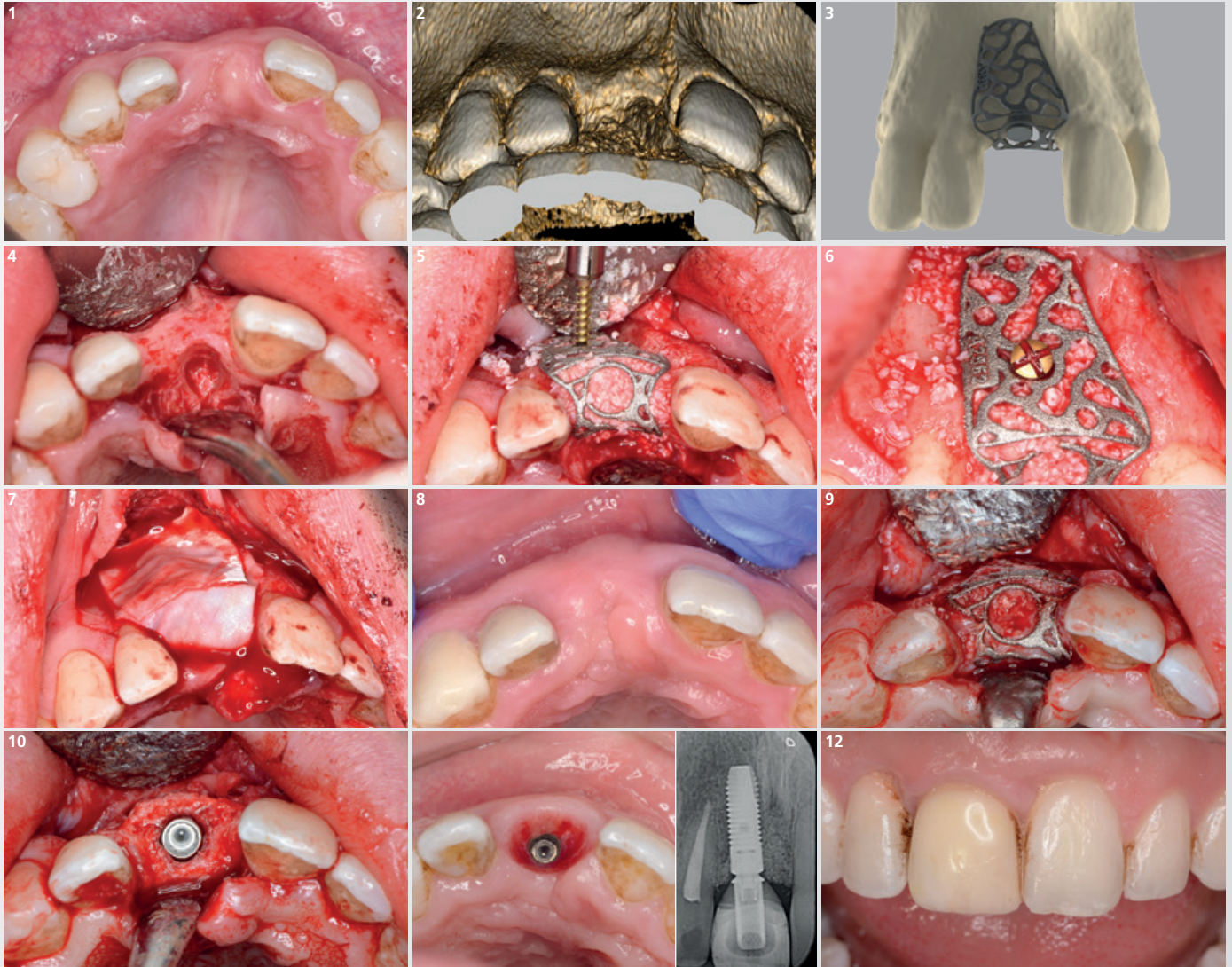
10 At time of implant placement, Geistlich Fibro-Gide® was used to augment the volume of the peri-implant soft tissues.

11 Final prosthetic rehabilitation demonstrates a successful integration of the restorations into the surrounding tissues.

12 Final prosthetic rehabilitation and radiographic follow-up 1 year after implant placement.

Horizontal/Vertical Defect (1 tooth gap) – Anterior Maxilla

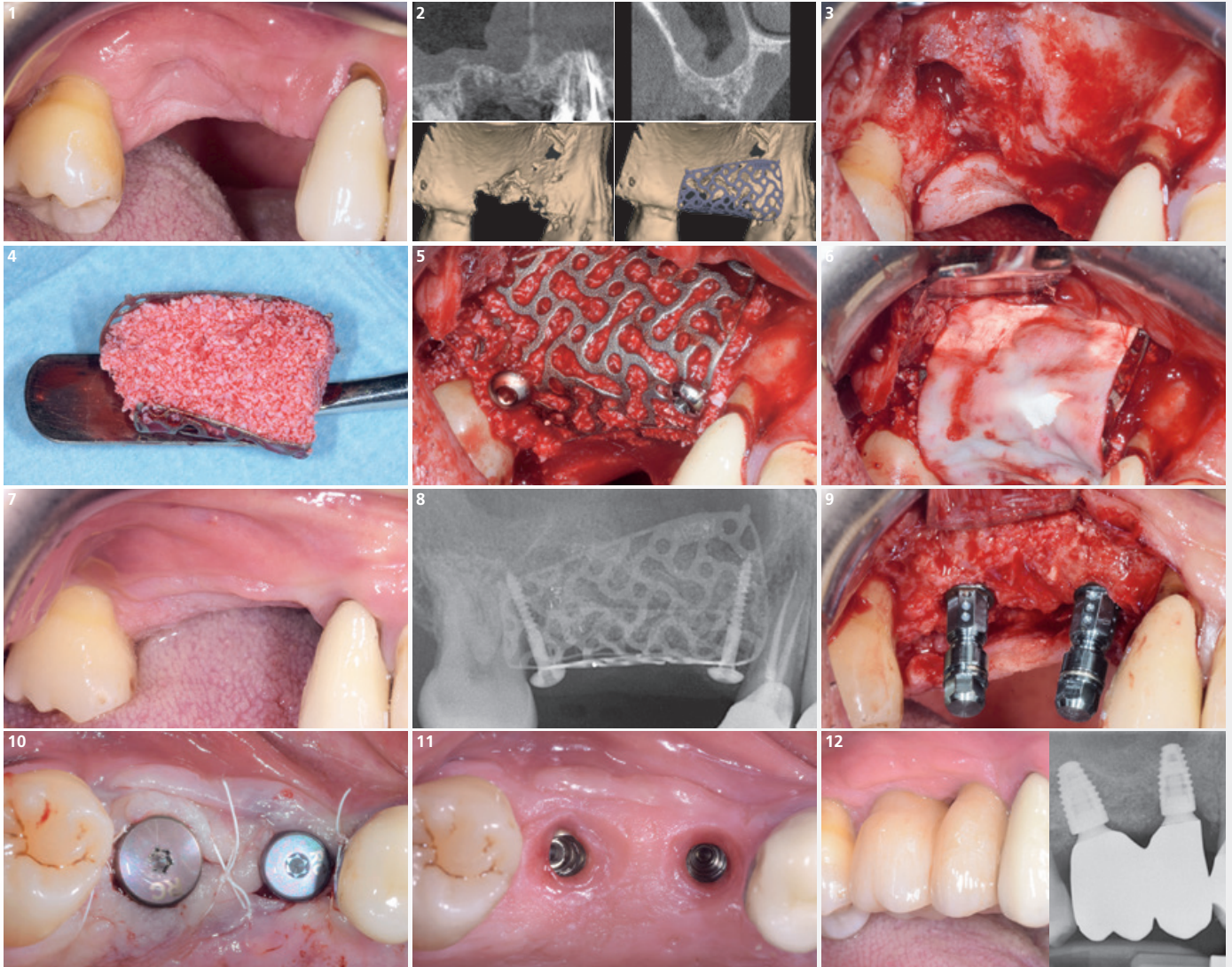
Surgery and concept by Dr. Daniel Saund (Birmingham, UK)



- 1 Initial presentation: 21 year old male with labial bony deficiency, thick soft-tissue biotype. History of trauma to tooth 11 which was subsequently extracted.
- 2 CBCT 3D rendered image of graft recipient site demonstrating labial bone deficiency and presence of large nasopalatine foramen inhibiting direct placement of implant.
- 3 Digital 3-D planning of the customized titanium scaffold by ReOss based on diagnostic imaging of the case.
- 4 Full thickness flaps raised, showing labial bony deficiency – further complicated by large nasopalatine foramen. Completed resection of nasopalatine nerve, showing tissue free bony margins to nasopalatine canal.
- 5 Before fixation Yxoss CBR® has been loaded with a mixture (50/50) of locally harvested autogenous bone and Geistlich Bio-Oss®.
- 6 Yxoss CBR® is secured in place with a single 12 mm screw.
- 7 Coverage of the graft area with a double layer of Geistlich Bio-Gide® followed by tension-free closure of the wound.
- 8 Presentation at 6 month review showing excellent healing and thick biotype has been maintained. Demonstrates the expansion of the ridge.
- 9 Buccal and palatal flaps raised showing Yxoss CBR® lattice in situ before its removal.
- 10 Yxoss CBR® removed, showing excellent integration and vascularization of Geistlich Bio-Oss®. Ridge demonstrated excellent width and height allowing the ideal positioning of the implant.
- 11 2 years post-operative view of soft tissue showing healthy gingivae with no evidence of gingival recession. This is reinforced by 2 year postoperative radiograph again confirming excellent maintenance of bone height around implant.
- 12 UR1 provisional crown in place with a view to replacing with a narrower definitive crown to match adjacent UL1 tooth width. Excellent gingival contour and adaptation to provisional restoration. (Kindly restored by K. Fairbrother, Birmingham)

Horizontal/Vertical Defect (2 teeth gap) – Anterior Maxilla

Surgery and concept by Dr. Daniele Cardaropoli (Turin, Italy)



1 Initial clinical situation showing an extended horizontal and vertical bone gap at former positions of teeth 15 and 16 which were extracted 8 weeks earlier.

2 CBCT showing a deficient vestibular contour and the corresponding bone defect. 3-D design of Yxoss CBR® derived from the patient's anatomy.

3 Surgical situation with horizontal and vertical bone defect.

4 After testing the adaptation of Yxoss CBR® to the defect, it is filled with a graft consisting of 30% autologous particulate bone and 70% granules of Geistlich Bio-Oss®.

5 Yxoss CBR® fixed with titanium screws.

6 Adaptation of Geistlich Bio-Gide® over the structure. Complete, tension-free wound closure will follow.

7 Clinical situation after 6 months of healing, before reopening. No adverse events have occurred.

8 Radiographic situation after 6 months of healing, before reopening.

9 Insertion of two implants (Straumann® BLT). The resonance frequency measurement shows ISQ values of 70-75.

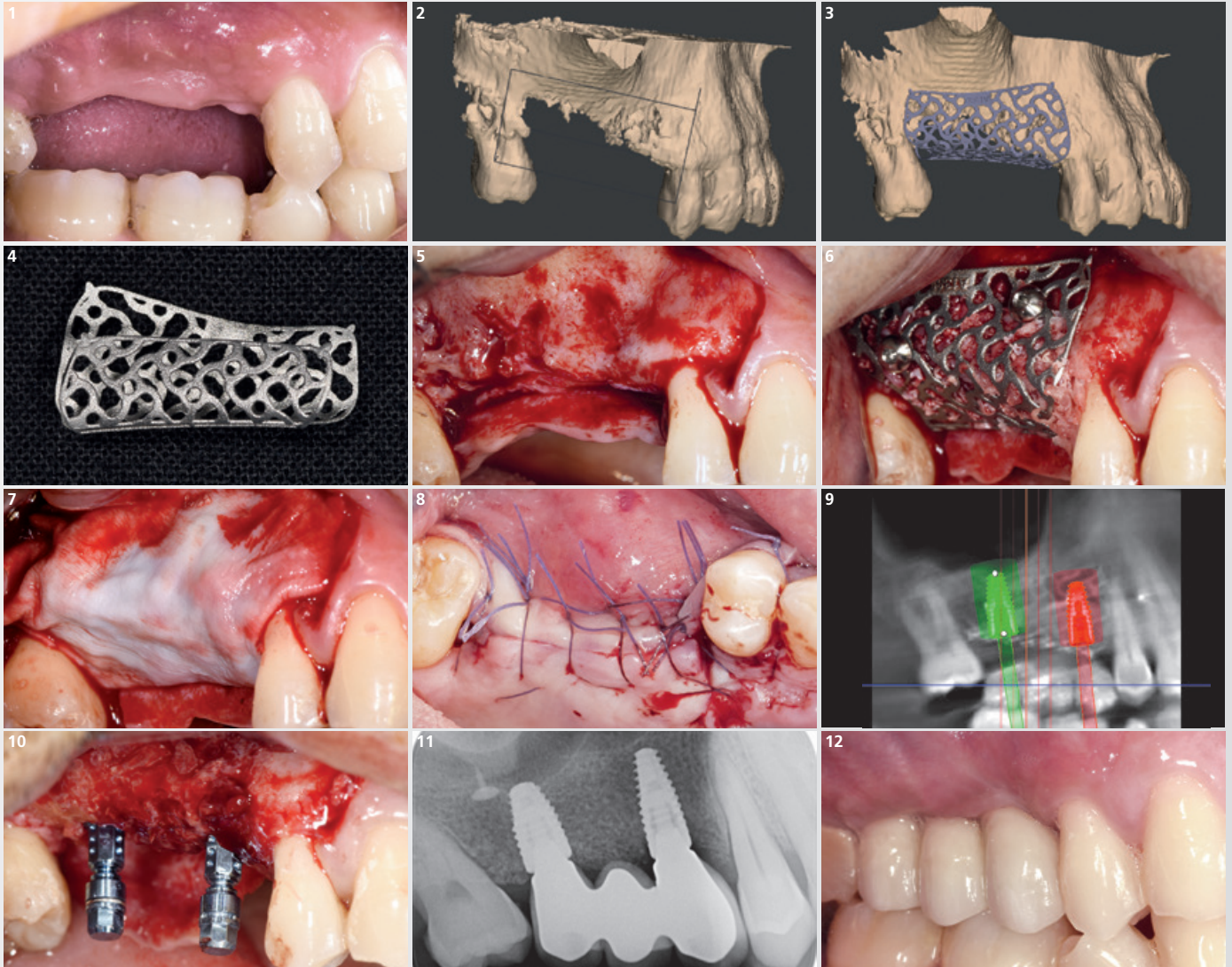
10 Insertion of the healing abutments and adaptation of the flap.

11 Soft tissue maturation 12 weeks after implant insertion.

12 Clinical situation after prosthetic finalisation, 18 months after surgery. X-ray shows stability of marginal bone levels.

Horizontal/Vertical Defect (3 teeth gap) – Anterior Maxilla

Surgery and concept by Prof. Matteo Chiapasco / Dr. Paolo Casentini (Milan, Italy)



1 Patient with missing teeth 14, 15, and 16 in combination with horizontal and vertical atrophy. Situation incompatible with ideal and prosthetically guided implant insertion.

2 Initial CBCT showing vertical and horizontal bone deficit.

3 3-D model obtained from CBCT with the corresponding Yxoss CBR® design.

4 Final titanium scaffold ready for use.

5 Exposure of the bone defect with full thickness flap.

6 Fixation of Yxoss CBR® filled with a mix of autologous bone chips and Geistlich Bio-Oss® using two titanium screws.

7 Coverage with a Geistlich Bio-Gide® membrane.

8 Tension-free hermetic suture of the flap.

9 After 8 months, the adequate rooting of the bone graft is assessed by CBCT and the insertion of the implants is planned in a prosthetically guided manner.

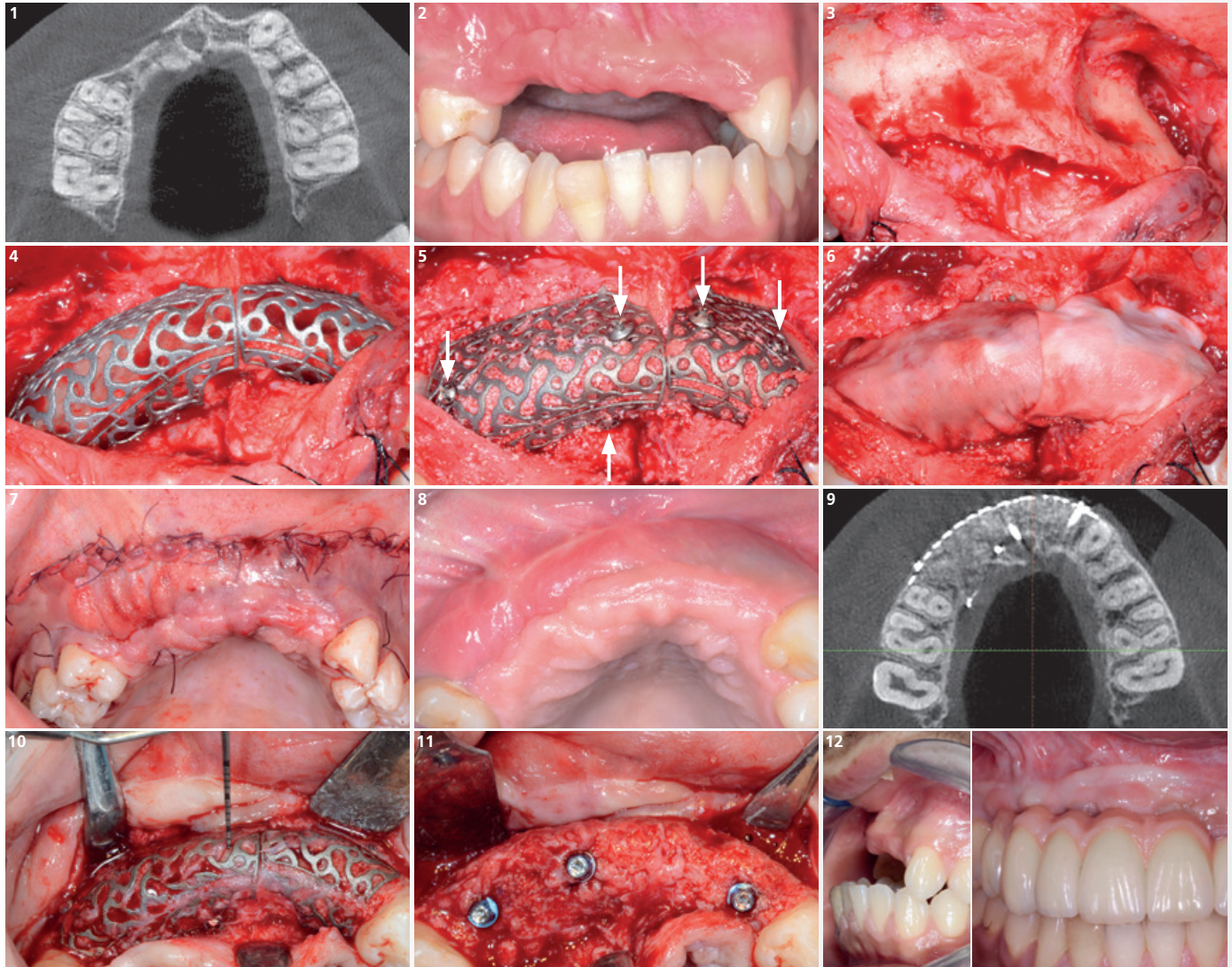
10 8 months after the GBR the scaffold is removed and two endosseous implants are inserted.

11 Radiography with three elements supported by implants.

12 Final prosthetic reconstruction 3 months after implant placement, without the need of a temporary interim solution.

Extended case (6 teeth gap) – Anterior Maxilla

Surgery and concept by Dr. Pierre Marin (Bordeaux, France)



1 Initial X-ray shows a partially edentulous space (teeth 14-22) and a horizontal bone defect due to a facial trauma caused by a traffic accident.

2 Clinical view of the vertical defect. Presence of post-traumatic reactive thick fibrous tissue [Lower incisor region underwent extrusion, vestibular migration, and distal displacement of teeth 41 and 42].

3 Based on split flap technique, flap elevation in palatal direction shows the extent of the bone defect. Note vertical defect combined with a lack of crestal thickness.

4 Intraoperative fitting of the scaffold. The design respects the anatomical elements (nasal spine, anterior palatal foramen).

5 Yxoss CBR® is filled with a 50:50 mix of autologous bone and Geistlich Bio-Oss® and stabilized by surgical screws (white arrows).

6 The scaffold is covered by a trimmed, but not fixed Geistlich Bio-Gide® membrane.

7 Flap is repositioned. At the upper vestibular incision, sutures are carried out in a deep (5-0 rapid resorption) and a superficial lane (5-0 slower resorption). They are completed with transpapillary sutures.

8 Uneventful healing. Transpapillary sutures were removed at 3 weeks. At 2 months, the vestibular profile of the arch has been rebuilt; slight transparency in region 22, and keratinized tissue has moved into marginal direction.

9 The tomographic image shows the perfect design of the scaffold to rebuild the maxillary contour.

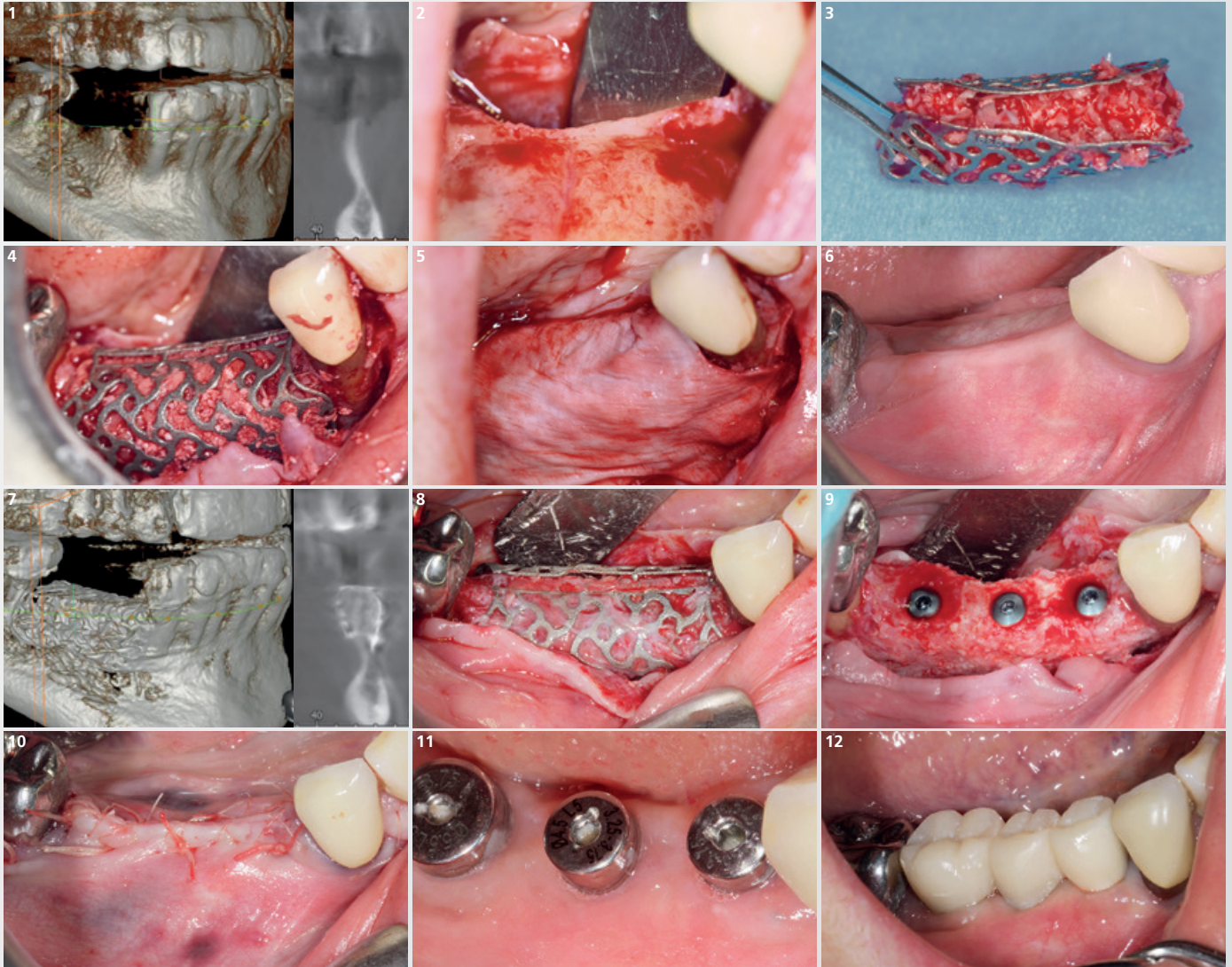
10 Upon removal after 6-7 months the scaffold is well-integrated and partially covered with a soft tissue layer. The periodontal probe measures 1.5 mm of immature tissue underneath.

11 Placement of implants. Notice that the crestal area is still weakly mineralized. This crestal immature tissue has to be preserved. Mineralization will continue along healing process.

12 Left: Clinical view of sagittal skeletal discrepancy (solved by 2 years of orthodontic treatment). Right: Final restoration (Dr. J. Leclair – Bordeaux) at 3.5 years. Artificial gingiva compensates antero-posterior skeletal defect.

Horizontal/Vertical Defect (3 teeth gap) – Posterior Mandible

Surgery and concept by Dr. Philippe Russe (Reims, France)



1 CBCT of initial situation showing the mandibular knife edge ridge.

2 Bony situation after full thickness flap.

3 Yxoss CBR®, filled with a mixture (50/50) of autogenous bone and Geistlich Bio-Oss® small granules.

4 Yxoss CBR® placed *in situ*.

5 A Geistlich Bio-Gide® collagen membrane is placed on top, covering the titanium scaffold.

6 Healing at 6 months postoperative: The scaffold is visible under the thin lingual gingiva.

7 Control CBCT at 6 months postoperative.

8 Separation of the Yxoss CBR® into two parts.

9 Implants placed in the bony reconstruction (BEGO Semados® SC).

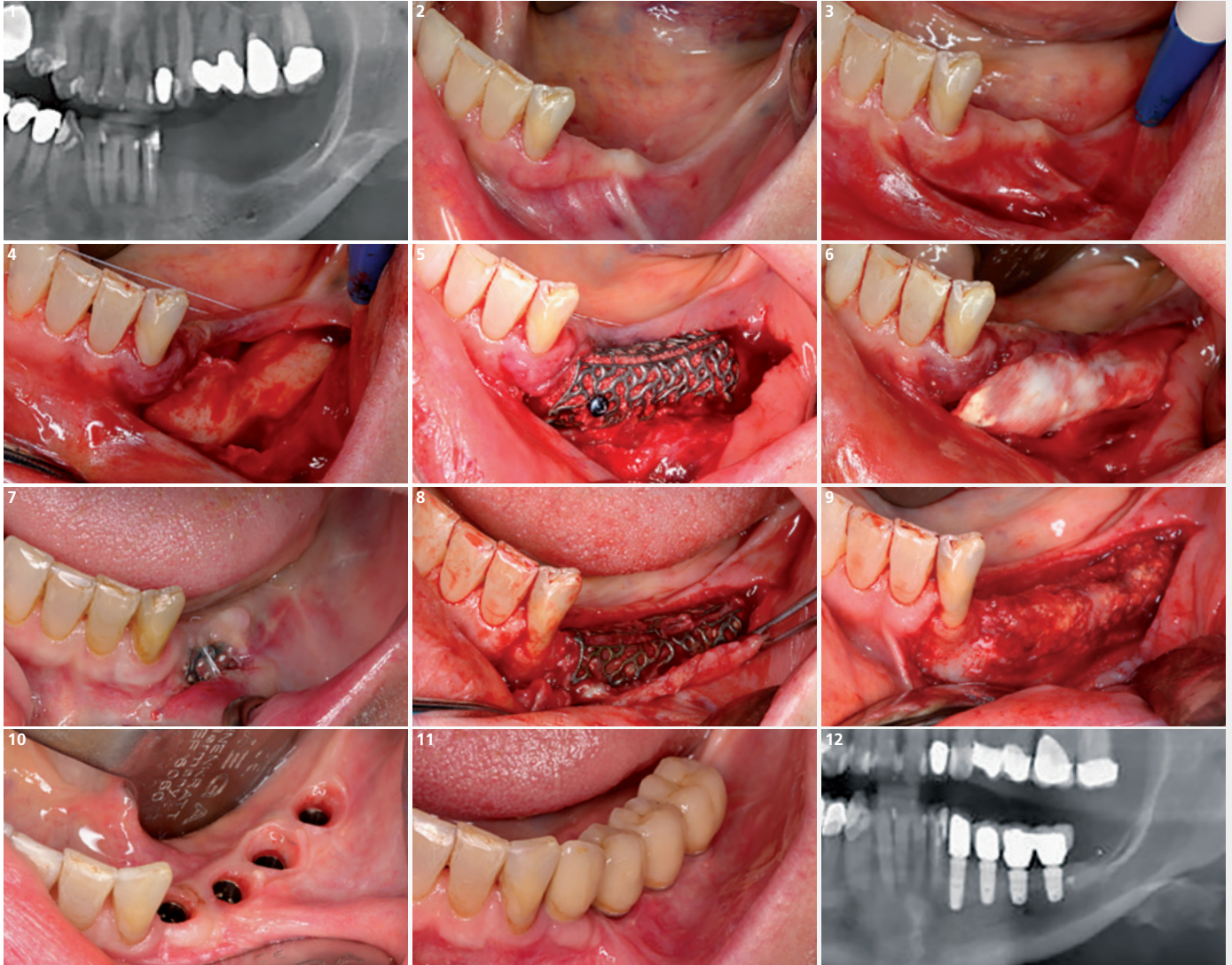
10 Additional GBR with Geistlich Bio-Oss® alone and Geistlich Bio-Gide® and suture with horizontal mattress (3/0) and crestal X sutures (6/0).

11 Attached gingiva created by a partial thickness flap around the healing abutments post uncovering of implants after a healing period of 6 months.

12 Provisional bridge at time of ceramic try-in.

Vertical Defect (4 teeth gap) – Posterior Mandible

Surgery and concept by Dr. Sarah Krause (Chemnitz, Germany)



1 Radiographic image showing the vertical bone deficit in the left mandible.

2 Clinical situation before opening the area.

3 Incision for the creation of a poncho flap.

4 Starting in the retromolar area the incision is directed toward the distal region of tooth 32.

5 Cortical bone is removed with the trephine, crushed and mixed with Geistlich Bio-Oss® (50:50).

6 Successive application of Geistlich Bio-Gide®.

7 Dehiscence after 1.5 months. The soft tissue was de-epithelialized and a free gingival graft was sutured to protect the exposition. Dehiscence may occur but usually heals spontaneously after appropriate cleaning.

8 After 6 months, the ridge incision is applied to access the 3-D titanium scaffold.

9 Buccal view of the regenerated bone. Even though there was dehiscence, the bone was regenerated satisfactorily.

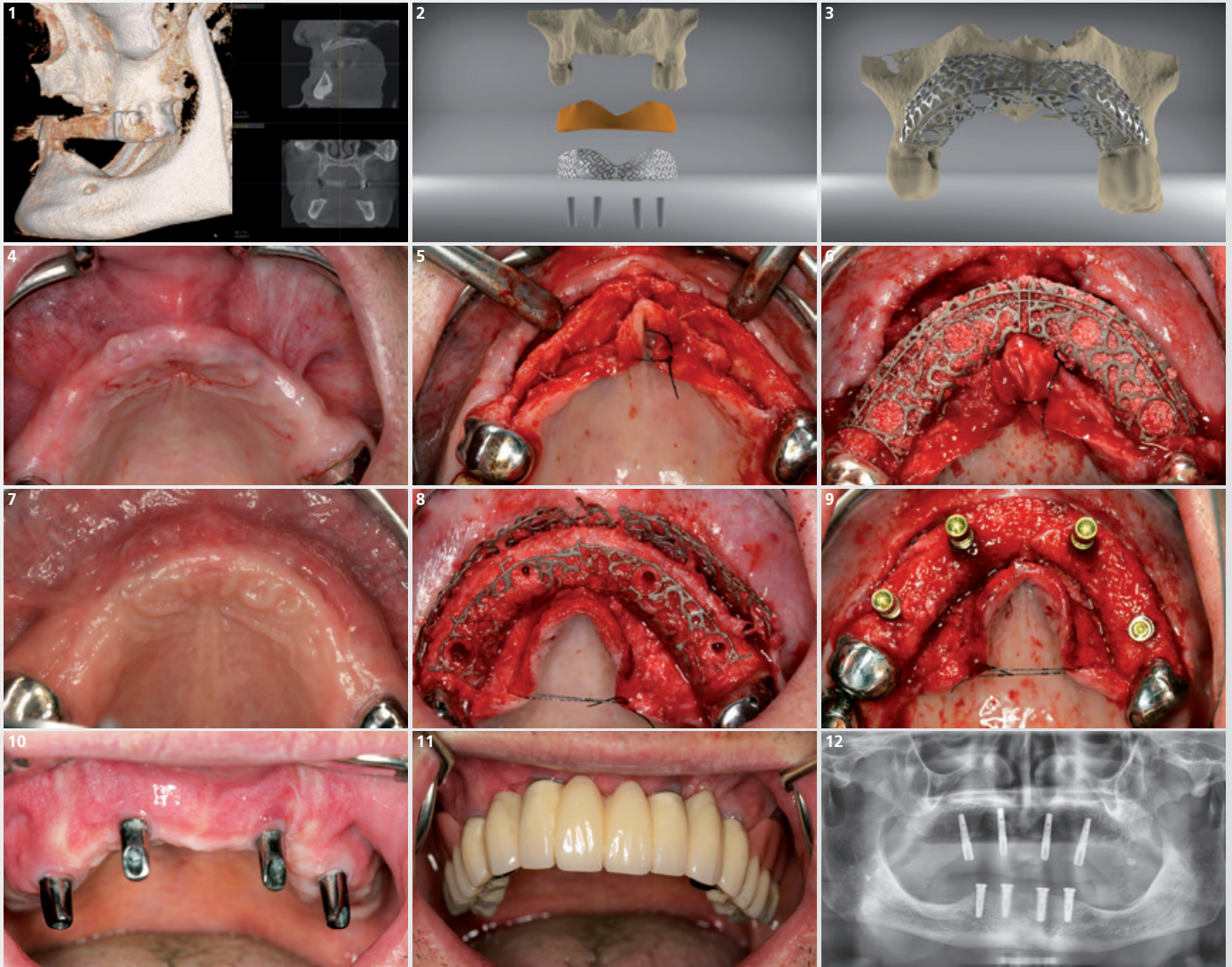
10 Four implants are inserted and the soft tissue is healed showing the contour provided by the good adaptation of the provisional prosthesis.

11 Clinical situation after the final prosthesis and the soft tissue frenum removal.

12 Radiographic situation.

Extended Case (8 teeth gap) – Maxilla

Surgery and concept by Dr. Marcus Seiler MSc MSc/Dr. Amely Hartmann (Filderstadt, Germany)



1 Large horizontal and vertical bone defect in region 14–24; deficit emerging from many years of wearing mucosa-supported dentures.

2 3-D design including 3-D model, grafting volume, Yxoss CBR® and implants.

3 3-D Design including 3-D model and Yxoss CBR®.

4 Initial clinical situation before opening of the soft tissue.

5 Presentation of bony situs with a full-thickness flap (ridge incision).

6 Titanium scaffold filled with 100% Geistlich Bio-Oss® and placed onto bone defect. Fixation performed with 4 mini-screws in the buccal area.

7 Soft tissue situation after 6 months of healing.

8 Careful separation of Yxoss CBR® into two parts at predetermined breaking points (Easy Removal Design®). Pilot drill performed through built-in holes according to backward planning principle.

9 4 implants placed in positions 14, 12, 22, and 24 to support the prosthesis. Bleeding out of the bone shows a good vascularization.

10 Situation 3 months after final prosthodontic treatment.

11 Incorporated final prosthetic restoration.

12 Panoramic X-ray 6 months after the augmentation. In the meantime, 4 additional implants have been placed in the lower jaw.

“This technique reduced the difficulties to less than half”

Interview with Prof. Matteo Chiapasco (Milan, Italy)

Prof. Chiapasco has used many surgical techniques to gain new bone height and width. Recently, he published his clinical experience with Yxoss CBR® (see summary of results on the right page).¹ What is key to success for him?

Prof. Chiapasco, what convinced you to try Yxoss CBR®?

Prof. Chiapasco: The available titanium meshes can be difficult to manipulate and fixate. I hoped that Yxoss CBR® would simplify the surgical procedure.

Did it?

Yes. And I have also significantly reduced operating times. Moreover the stability and accuracy of the reconstruction are amazing. You can visualize the reconstruction in 3-D before you start surgery and calculate the amount of graft material needed. And by using Yxoss CBR® I avoid more traumatic harvesting and sampling

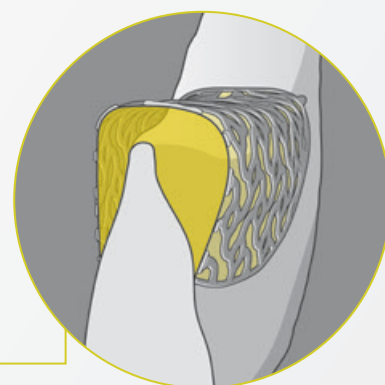
of bone blocks. I only use bone chips – mainly harvested from intraoral sites – and Geistlich Bio-Oss®.

How much height and width can you gain with Yxoss CBR®?

Theoretically, there are no significant limits to bone augmentation, neither vertically nor horizontally. In some cases, I gained 10 mm in height. But we can arbitrarily divide bone augmentations into three categories: 1–3 mm, 4–6 mm, and > 6 mm. The bigger, the more difficult. Vertical augmentations can be more demanding than horizontal, especially for less experienced surgeons.

How would you convince a colleague to try Yxoss CBR®?

While it is important to be an expert in GBR, this technique reduces the difficulties to less than half and is predictable, effective, and precise. Try it to believe it.



In major bone augmentation, dehiscences are a frequent problem. How often do you experience such complications when using Yxoss CBR®?

If we included all exposures, the incidence is approximately 20%. But most of them do not compromise the outcome, especially if they occur in later stages of graft inte-

gration. Severe early dehiscences with loss of the grafts happened in less than 5% of our cases.

What is key to avoid dehiscences?

Many factors can reduce this risk: 1) Working in sterile conditions; 2) Accurate and significant flap release to get a tension-free and hermetic suture; 3) Good quality of soft tissues; 4) No load with removable prostheses on the regenerated areas.

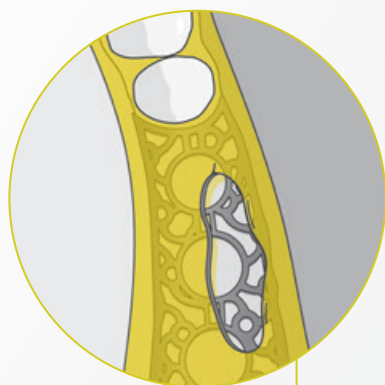
If dehiscences occur, how do you proceed? Will they disturb bone healing?

If the dehiscence occurs immediately after surgery, the risk of relevant loss of the grafting material is higher. The particulated graft is more exposed and is not yet integrated. I do not recommend re-suturing the flaps, though. It could increase

the infection risk as the mesh might be covered by a film of bacteria. If signs of infection are evident, in particular suppuration, I recommend removing the mesh, allowing the grafting material to cover with granulation tissue and re-evaluating after a few weeks. Despite this unfavorable event, part of the original graft may still integrate.

If the dehiscence occurs later, there is a high chance that granulation tissue has formed below the exposed parts and will protect the graft. In this case, oral hygiene measures such as chlorhexidine mouth rinses and frequent recalls will allow to maintain the majority of the graft.

Antibiotics are helpful in the first week after surgery. But in the early phases the graft is poorly vascularized, and antibiotics hardly reach the target.



100% implant survival rate after loading No biological or prosthetic complications

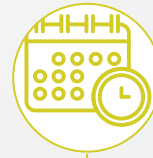
A summary of Chiapasco et al. 2021



Retrospective
single-arm
study



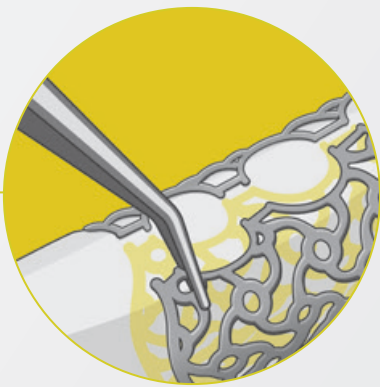
41 (53 sites)



11 months*
after loading



Yxoss CBR®
Geistlich Bio-Oss®
Geistlich Bio-Gide®
Autologous bone



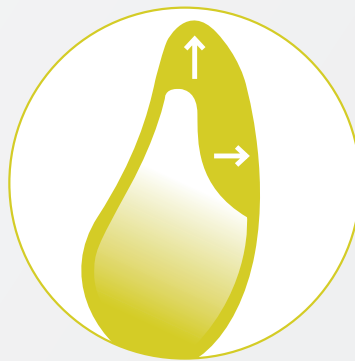
Mesh removal can be difficult. What is your experience with Yxoss CBR®?

Mesh removal is one of the most delicate phases of the whole regeneration procedure. During healing, the bone graft can even “submerge the mesh” with new bone formation, thus rendering its removal more complex. Plus, soft tissues overlying the mesh are generally thin and penetrate through the mesh. Extreme accuracy must be ensured to separate soft tissue and the consolidated bone grafts from the mesh.

Do you have advice on how to make mesh removal easier?

Wait at least seven to eight months and... good and trained hands, and delicate, attentive measures!!!

Bone gain



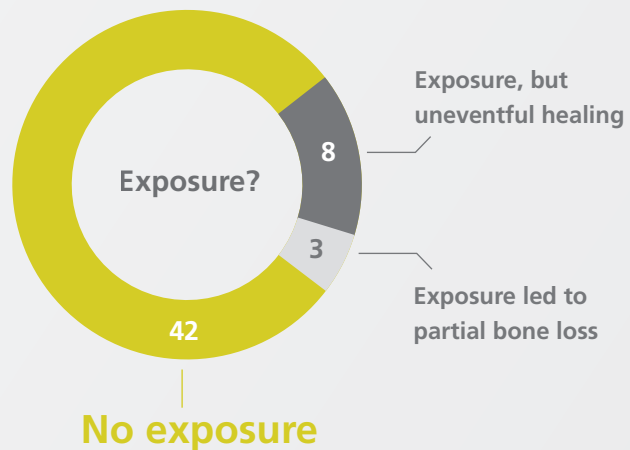
Vertical bone gain

↑ **4.78 ± 1.88 mm**

Horizontal bone gain

→ **6.35 ± 2.10 mm**

Exposures



Prof. Matteo Chiapasco



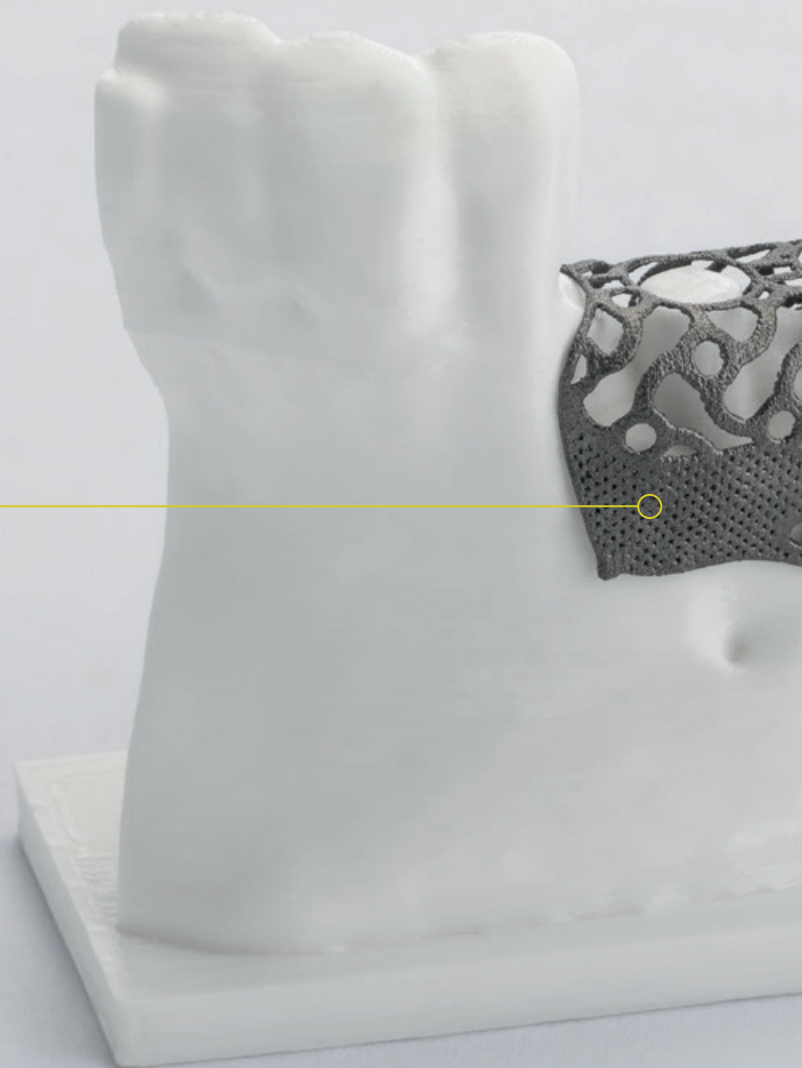

¹ Chiapasco M, et al: Clin Oral Implants Res 2021; 32(4): 498-510.
* (mean = 10.6 months; range: 2 - 26; median = 10.6; SD = 6.49)

Yxoss CBR[®] protect – Designed for an even easier removal

The open structure of Yxoss CBR[®] classic enables periosteal vascularization that is essential for bone regeneration. In certain cases, excessive bone formation in the apical part of the titanium scaffold can hamper its removal due to soft and hard tissue ingrowth. To overcome this challenge Yxoss CBR[®] protect features a microporous structure in the apical area which allows an even easier removal.

Dense microstructure for apical edge zones¹

- › Protects the apical area from soft and hard tissue ingrowth
- › Enables even easier removal



¹ Manufacturing result may visually differ from rendered microstructure.

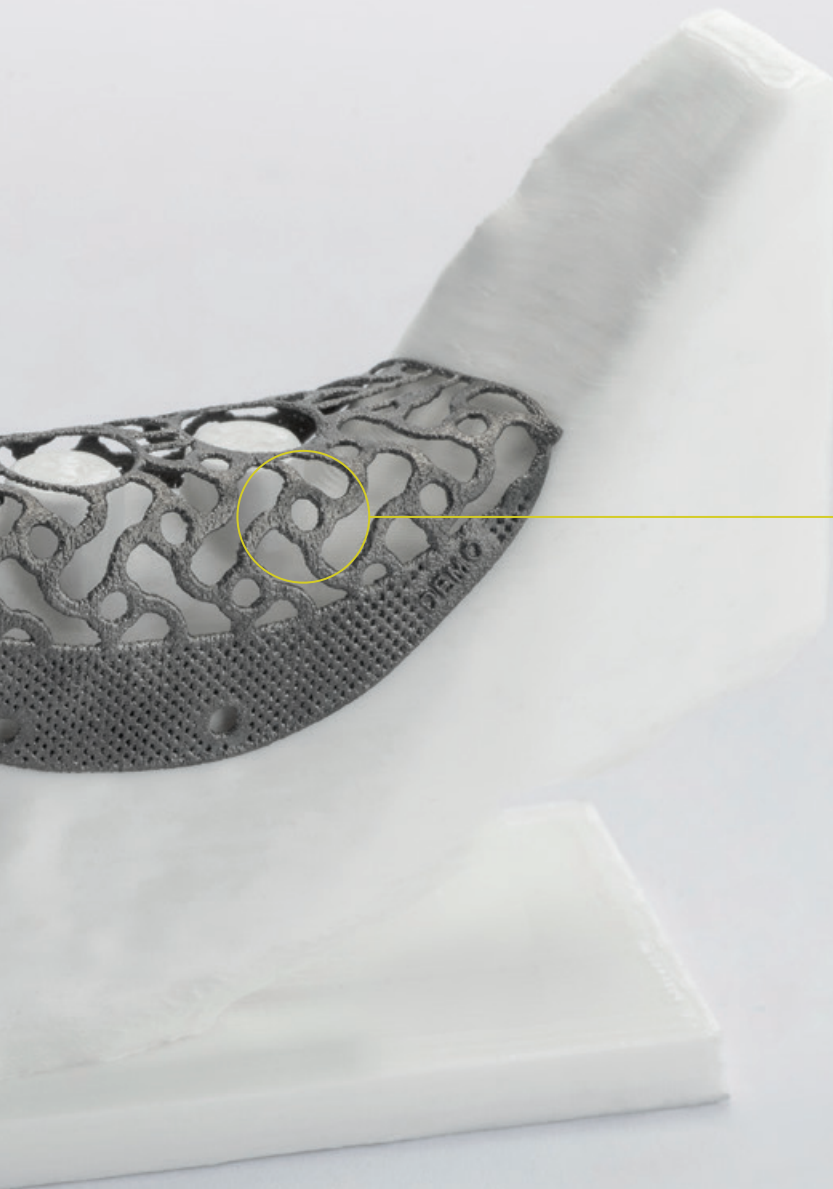

Biological background

Periosteal nutrition: +++

Maturation of the bone is dependent on the vascularization of the periosteal vessels

Ingrowth of soft and hard tissue: NO

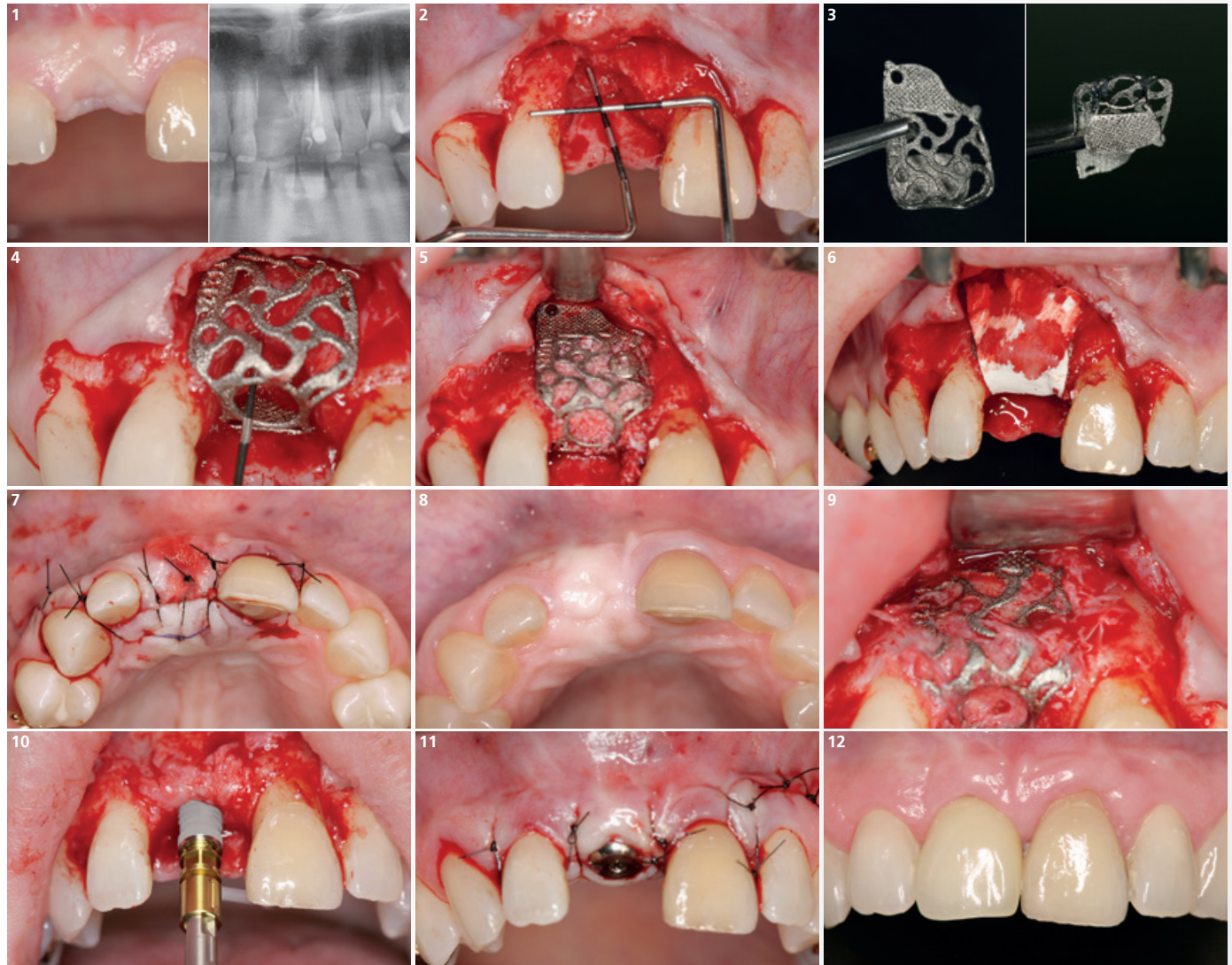
Higher occlusivity due to denser Yxoss CBR® protect structure leads to less intergrowth with tissue cells



In the upper part of the scaffold, the periosteal blood supply continues to be promoted by the open structure

Horizontal/Vertical Defect (1 tooth gap) – Anterior Maxilla

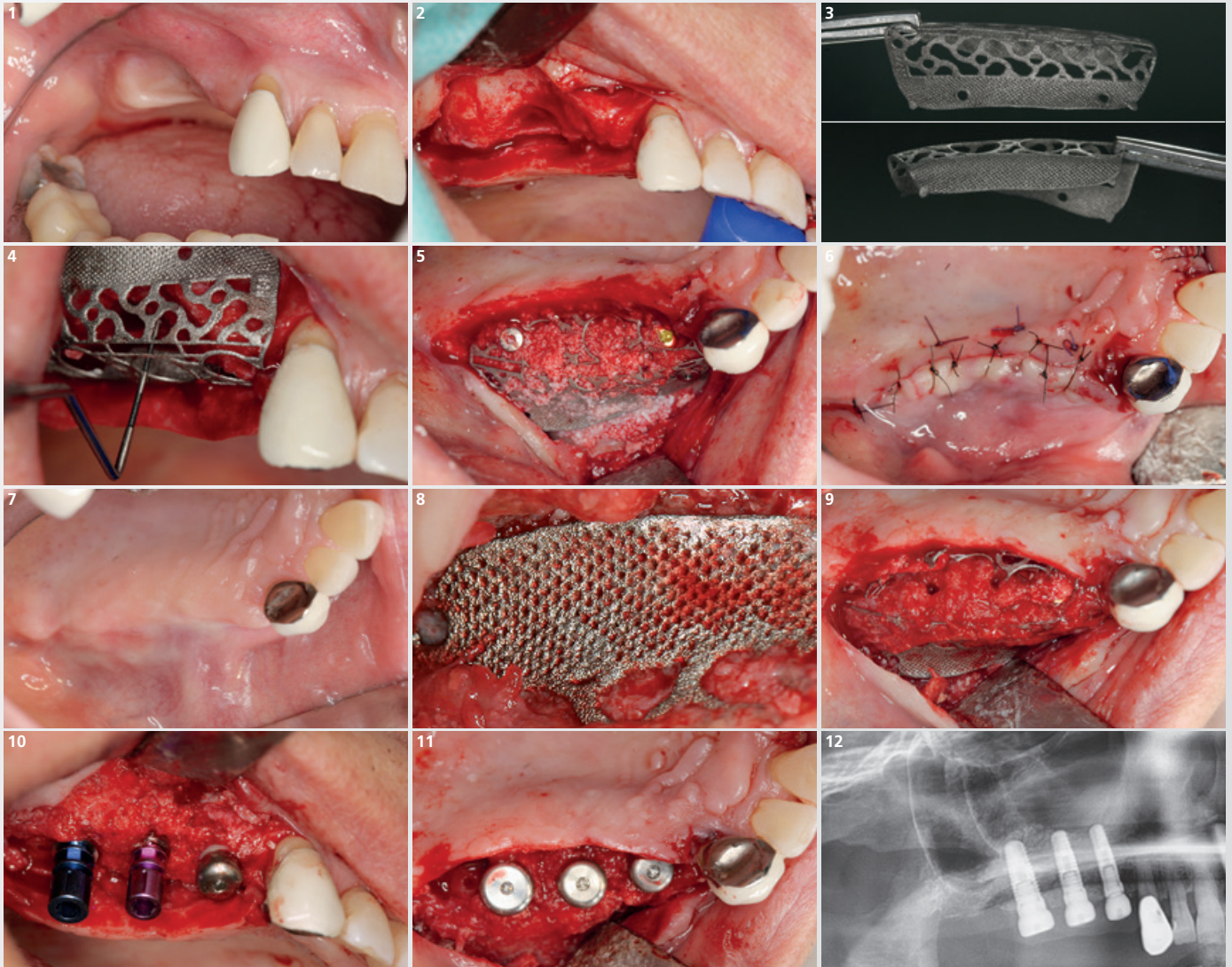
Surgery and concept by Dr. Marcus Seiler MSc MSc (Filderstadt, Germany)



- 1** Clinical baseline situation before reconstruction in the aesthetic zone (region 11) with Yxoss CBR® protect.
- 2** Horizontal and vertical bone defect visible after palatally displaced ridge incision (flap extended mesially and distally by width of 1-2 teeth).
- 3** Defect augmented using Yxoss CBR® protect design to prevent the ingrowth of hard and soft tissue in the apical area.
- 4** The Titanium scaffold customized via CAD/CAM fits perfectly to the bone defect measuring 6 mm in vertical dimension.
- 5** The prefilled Yxoss CBR® protect is fixed with a single FYxoss screw.
- 6** The defect site is covered with a Geistlich Bio-Gide® collagen membrane.
- 7** Double layer flap closed tension-free over Yxoss CBR® protect using resorbable deep mattress and single interrupted sutures.
- 8** Clinical situation 7 months after the augmentation.
- 9** Easier removal of the Yxoss CBR® protect after the regeneration: no in-growth of hard and soft tissue observed in the apical area due to the "protect" structure.
- 10** After removal of the Yxoss CBR® protect an endosseous implant is inserted into the regenerated ridge.
- 11** The high quality of the regenerated bone allows for a transgingival healing.
- 12** Clinical situation after prosthetic treatment with a full ceramic crown & radiologic imaging 4 months post-implant insertion.

Horizontal/Vertical Defect (3 teeth gap) – Posterior Maxilla

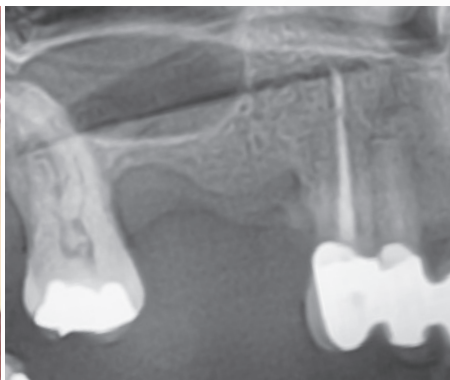
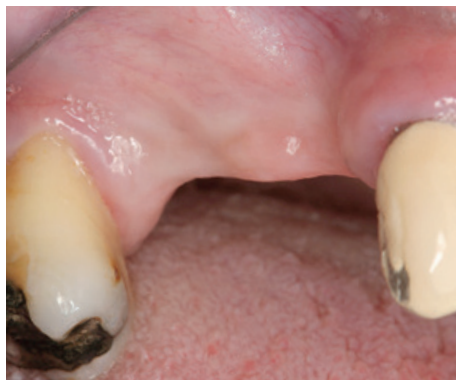Surgery and concept by Dr. Marcus Seiler MSc MSc (Filderstadt, Germany)



- 1 Clinical baseline situation of the vertical and horizontal defect.
- 2 Vertical and horizontal bone defect after surgical opening via a mid-crestal incision.
- 3 3-D printed Titanium scaffold with pre-specified fixation options in the apical area of the „protect“ structure.
- 4 Try-in of Yxoss CBR® protect into the defect region. A bone defect of approx. 6 mm is revealed.
- 5 The scaffold is fixed with a single FYxoss screw in the crestal area. In accordance with the backward planning one implant could be inserted immediately (pos. 14). In addition an external sinus lift was performed.
- 6 Tension-free closure of the double layer mucoperiosal flap over Yxoss CBR® protect using resorbable deep mattress and single interrupted sutures.
- 7 Clinical image shows an irritation-free healing after the extensive horizontal and vertical augmentation.
- 8 Yxoss CBR® protect successfully prevented hard and soft tissue ingrowth in the apical area. The bone maturation was not affected.
- 9 Thanks to the Yxoss CBR® protect design the scaffold could be removed more easily after a healing period of 6 months.
- 10 Fully regenerated and matured bone with implants.
- 11 After inserting the two additional implants and the healing abutments the flap is closed once again.
- 12 Radiographic image visualizes the implant positions within the regenerated bone.

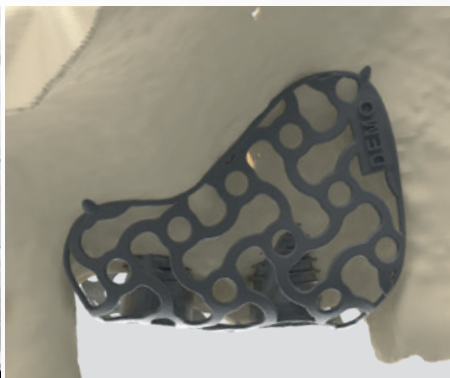
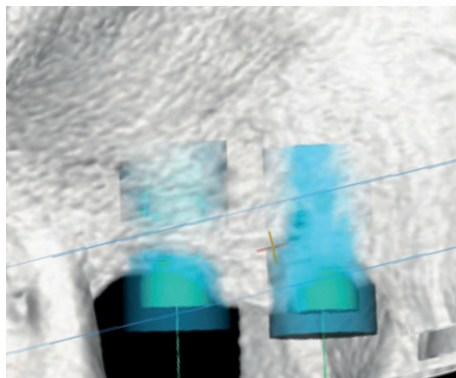
Yxoss CBR[®] backward

Have you ever customized the regenerative procedure together with a surgery guide for correct implant placement? ReOss offers the option of integrated 3-D implant positioning in the surgical planning called Yxoss CBR[®] backward.



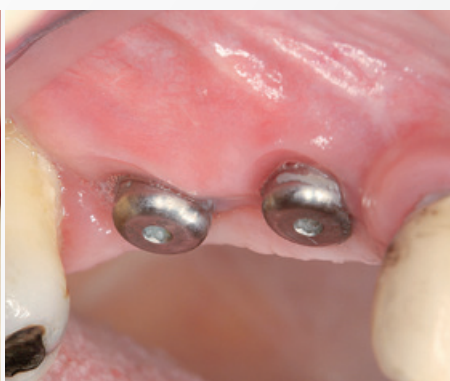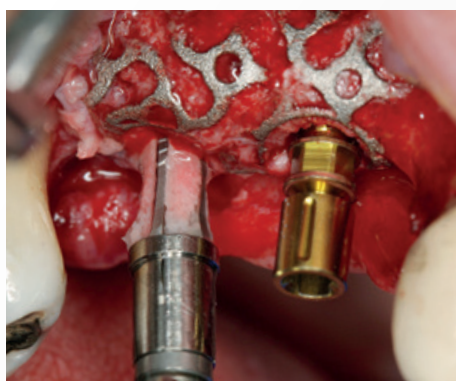1. Diagnosis & order:

When placing your order upon diagnostic imaging you can select the option Yxoss CBR[®] backward which will allow you to use the Yxoss CBR[®] scaffold as your surgical guide for implant positioning.



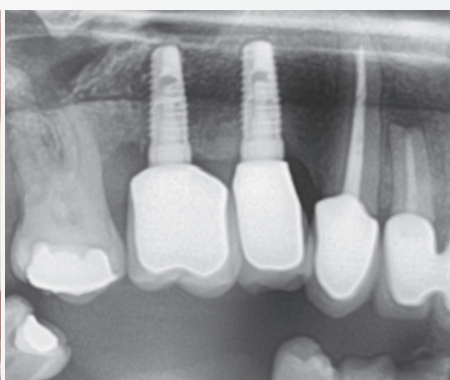
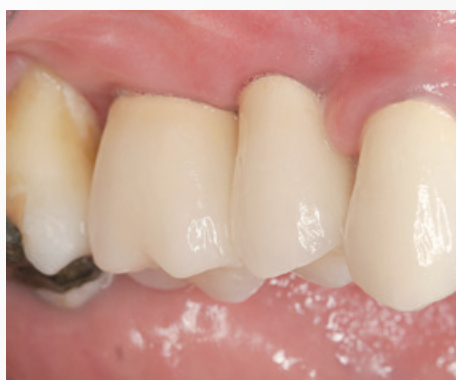2. 3-D planning & design:

You will receive the proposal for the digital 3-D design with the opening provided for future positioning of the implant pilot drill. After sending your design approval to ReOss, you will receive the Yxoss CBR[®] scaffold for sterilization and implantation.



3. Implant placement:

During simultaneous approach or at the time of reopening, Yxoss CBR[®] backward with its pre-existing openings can serve as your surgical guide for the positioning of the implant pilot drill. Further implant insertion steps can be performed after the removal of the scaffold.

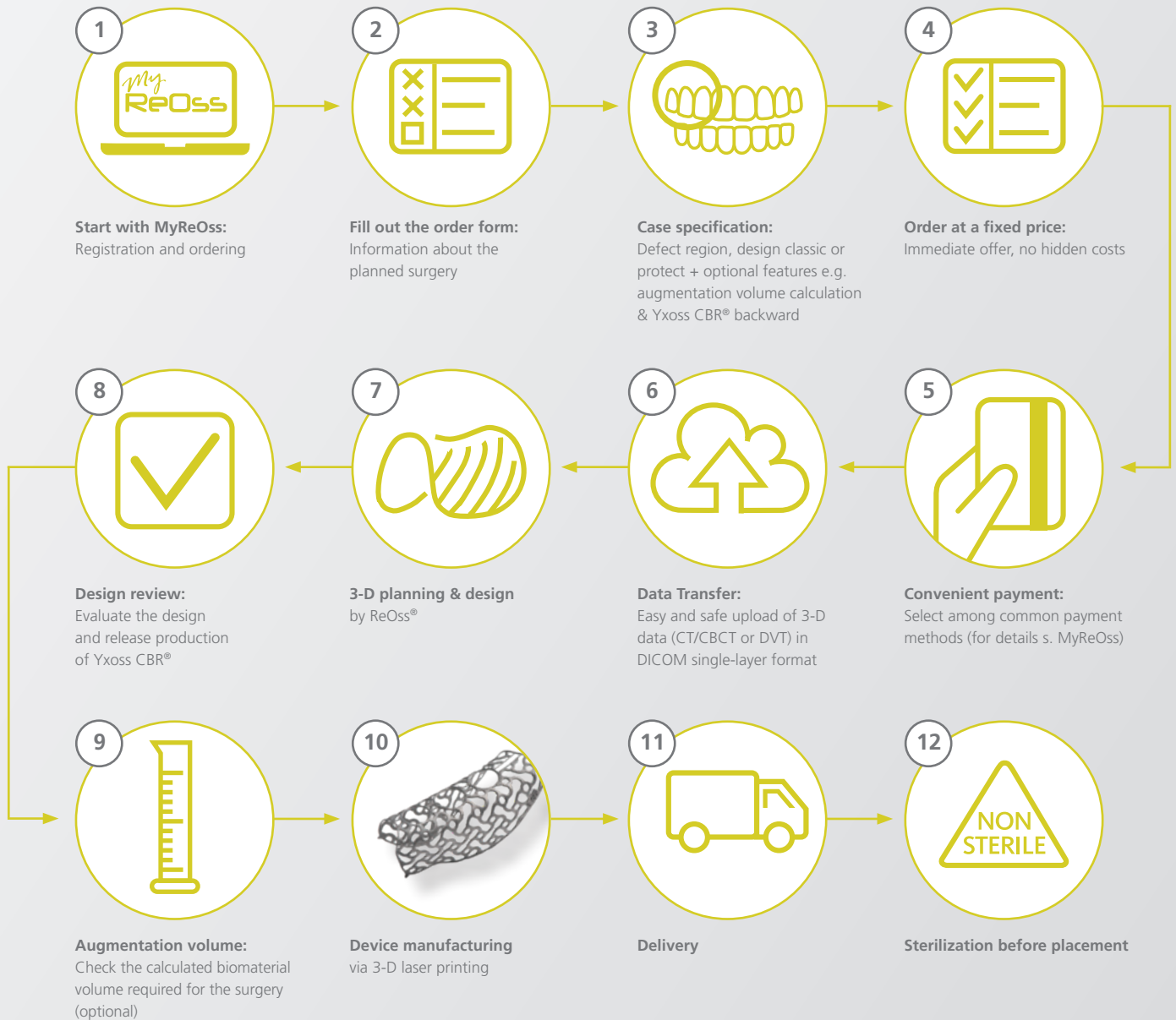

4. Prosthetic outcome:

Once the healing process of bone and mucosa is complete the prosthetic crowns can be placed to finalize the treatment.

How to order

The intuitive online ordering platform MyReOss (www.reoss.eu/myreoss) allows you to upload imaging files and to easily monitor all steps of the entire process at any time in your personal account. Moreover, MyReOss offers full transparency concerning pricing and proposals for the amount of regenerative biomaterials needed to augment the defect-specific volume.



For general questions about product and ordering process, please contact your local Geistlich Biomaterials representative:

www.geistlich-pharma.com/mycontact

For specific questions about your order, case planning, 3-D design, and your customer account, please contact ReOss LLC:

E-mail: contact@reoss.eu

Tel. +49 711 489 660 60 / Fax +49 711 489 660 66

www.reoss.eu

Yxoss CBR®

Easy ordering at
www.reoss.eu/myreoss




Customized Solutions

ReOss® LLC

E-mail: contact@reoss.eu
Tel. +49 711 489 660 60
Fax +49 711 489 660 66
www.reoss.eu

marketed by
Geistlich
the regeneration
experts



Geistlich Bio-Oss®

Stable scaffold for new bone.^{1,2,3,4} The slow resorption of Geistlich Bio-Oss® increases the stability of the augmentation material⁵ – the best prerequisite for long-term implant survival rates.⁶



Geistlich Bio-Gide®

Stabilizes the grafted area and protects bone particles from dislocation for optimal bone regeneration.⁷ The natural collagen structure allows homogeneous vascularization, supports tissue integration and wound stabilization.⁸ The combination of flexibility, good adhesion, and tear resistance contribute to easy handling, in turn saving time, and simplifying the surgical procedure.⁹

1 Orsini G et al., J Biomed Mater Res, B: Appl Biomater 74B, 2005; 448–57.

2 Piattelli M et al., Int J Oral Maxillofac Implants 1999; 14: 835–40.

3 Sartori S, et al., Clin Implants Res 2003; 14: 369–72.

4 Traini T et al., J Periodontol. 2007 May; 78(5): 955–961.

5 Orsini G et al., Oral Diseases. 2007; 19: 357–368.

6 Jung R et al., Clin Oral Implants Res. 2013 Oct; 24(10): 1065–73.

7 Perelman-Karmon M et al., Int J Periodontics Restorative Dent. 2012 Aug; 32(4): 459–65.

8 Rothamel D et al., Clin. Oral Implants Res. 2005; 16(3): 369–378.

9 Data on File. Geistlich Pharma AG, Wolhusen, Switzerland.



For more information, please visit:

www.reoss.eu

www.geistlich-pharma.com

CAUTION: Federal law restricts these devices to sale by or on the order of a dentist or physician. For more information on contraindications, precautions, and directions for use, please refer to the Instructions for Use at: dental.geistlich-na.com/ifu